Hudek R., Werner B., Gohlke F. Infections in elbow arthroplasty. Issue Rehabil. Orthop. Neurophysiol. Sport Promot. 2016; 14: 13–20.

INFECTIONS IN ELBOW ARTHROPLASTY

Robert Hudek
Birgit Werner
Frank Gohlke
Rhön Klinikum AG, Klinik für Schulter- und Ellbogenchirurgie, Bad Neustadt, Germany

SUMMARY
In elbow arthroplasty, a special attention is attributed to postsurgical infections because many patients have predispositions like rheumatoid arthritis and consecutive immunosuppression. In cases of revision arthroplasty different strategies to eradicate the bacteria and to restore joint function are discussed. We aimed to expose detection methods of postsurgical infections including low-grade infections, therapy approaches and surgical procedures for the treatment of an infected elbow arthroplasty.

Keywords: elbow infection, arthroplasty infection, postsurgical infection

Date received: January 19, 2016
Date accepted: February 19, 2016

INFEKCJE W PRZYPADKACH ENDOPROTEZOPLASYKI ŁOKCIA

Robert Hudek
Birgit Werner
Frank Gohlke
Rhön Klinikum AG, Klinik für Schulter- und Ellbogenchirurgie, Bad Neustadt, Niemcy

STRESZCZENIE
W przypadkach endoprotezoplastyki łokcia, szczególną uwagę przykłada się do ewentualnych zakażeń pooperacyjnych, ponieważ wielu pacjentów wykazuje w tym kierunku predyspozycje, takie jak reumatoidalne zapalenie stawów i jego leczenia immunosupresyjne. W przypadku zabiegu rewizyjnego, stosuje się i dyskutuje różne strategie w celu wyeliminowania bakterii i przywrócenie funkcji stawu. Celem tej pracy było przedstawienie metod wykrywania zakażeń po zabiegach, w tym zakażeń o niskim stopniu złośliwości, metod leczenia i zabiegów chirurgicznych w leczeniu zakażonego łokcia po endoprotezoplastyce.

Słowa kluczowe: infekcje łokcia, infekcje towarzyszące endoprotezoplastyce, infekcje po zabiegach chirurgicznych

Data otrzymania:19 stycznia, 2016
Data zaakceptowania: 19 luty, 2016

Introduction

Postoperative infections after elbow arthroplasty range between 0.5–9% in literature (Fevang *et al.* 2009; Plaschke *et al.* 2014). However, the incidence is declining over the recent decades. In 1996, Gschwend *et al.* reported a rate of 9% (Gschwend *et al.* 1996) whereas the Danish elbow registry recorded only 1.5% in 2014 (Plaschke *et al.* 2014). This represents a six-fold reduction in approximately 20 years. A review of literature from 2011 reported a rate of 3.3 ± 2.9% across different studies and registries (Voloshin *et al.* 2011). The infection rate changes dramatically if the arthroplasty is performed after a previously failed osteosynthesis for fracture treatment. Data from our department show an infection rate of 20% in these cases. The pathogenicity of bacteria greatly differs (Trampuz *et al.* 2003). Gram-positive bacteria show a relative benign profile with regard to the effectiveness of antibiotics in most cases. Gram-negative germs are cultured typically in very old patients and in

contrast, commonly share multidrug resistances. In these cases combinations of antibiotics or very expensive reserve antibiotics are often necessary to eradicate the infection.

Aim, patients, method

Postsurgical infections can be devastating in elbow arthroplasty. The bone stock is often very limited which makes revision surgery a demanding procedure. In this report, we aimed to expose detection methods of postsurgical infections including low-grade infections, therapy approaches and surgical procedures for the treatment of an infected elbow arthroplasty by a review of relevant literature on these topics.

Results

Rheumatoid patients with strong or long lasting inflammatory activity represent the main candidates for elbow arthroplasties, which makes them simultaneously prone to postsurgical infections. The patient's immunosuppressive medication needs to be paused for several weeks or months prior to implantation. As a result of an immunosuppressant, a combination of multiple bacteria can be observed in these patients, which is challenging with respect to the antibiotic regimen. In 30% of infected cases the bacteria produce bio-films (Trampuz *et al.* 2003). A complete removal of all implanted foreign bodies, including bone cement is therefore mandatory for successful treatment (Hudek and Gohlke 2013). Otherwise these bacteria will hide underneath the bio-film. Their adhesion to an inert surface makes them inaccessible for antibiotics. A field of special interest is the "low-grade" infection most often caused by *Propionibacterium acnes* (*P. acnes*) (Hudek *et al.* 2014; Hudek *et al.* 2016). It has been reported multiply in cases of implant-associated infections (Achermann *et al.* 2013; Levy *et al.* 2013; Hudek *et al.* 2014; Sethi *et al.* 2014). *P. acnes* can hide intracellular in macrophages and produces a bio-film (Bruggemann 2005; Bruggemann *et al.* 2012; Fischer *et al.* 2013). Low-grade infections typically evolve very slowly, sometimes over years. Clinical manifestations of local redness, swelling or fever are often missing (Hudek *et al.* 2016). Therefore, conclusive diagnostics are of critical importance. In shoulder surgery, *P. acnes* were observed in 36% of patients during first-time surgery in different tissue layers (Hudek *et al.* 2014). The risk of obtaining *P. acnes* positive cultures has also been linked to loss of hair (Hudek *et al.* 2016). If patients reported to have loss of hair they were not found to have *P. acnes* positive cultures during shoulder surgery (Hudek *et al.* 2016). If this is also true in open elbow surgery remains to be substantiated.

The classification for postoperative infections is typically divided into the four fields: early, delayed, late and low-grade infections (Hudek and Gohlke 2013). An "early infection" appears within one month after surgery and can be attributed most often to exogenic causes rather than displacement of the bacterium via haematogenous seeding. A "delayed infection" is found between 3 months and 2 years after the surgery. The "late infection" is observed after at least 2 years and can be subdivided in acute cases, which show symptoms within 3 weeks, or chronic cases that show a course of symptoms for more than 3 weeks.

The therapy regimen for the treatment of an infected elbow arthroplasty has to include several factors (Figure 1). Risk factors include diabetes, rheumatoid arthritis, chemotherapy or congenital immune diseases, neurodematosis or i.v. drug abuse.

In acute cases of early infections, an arthroscopic debridement can be performed as an emergency aid in order to prevent septicemia and to decompress and drain an empyema. However, the success rate is reportedly weak (15%) even with the combination of systemic antibiotics (Mastrokalos *et al.* 2006). Therefore, open debridement is the therapy of choice in cases

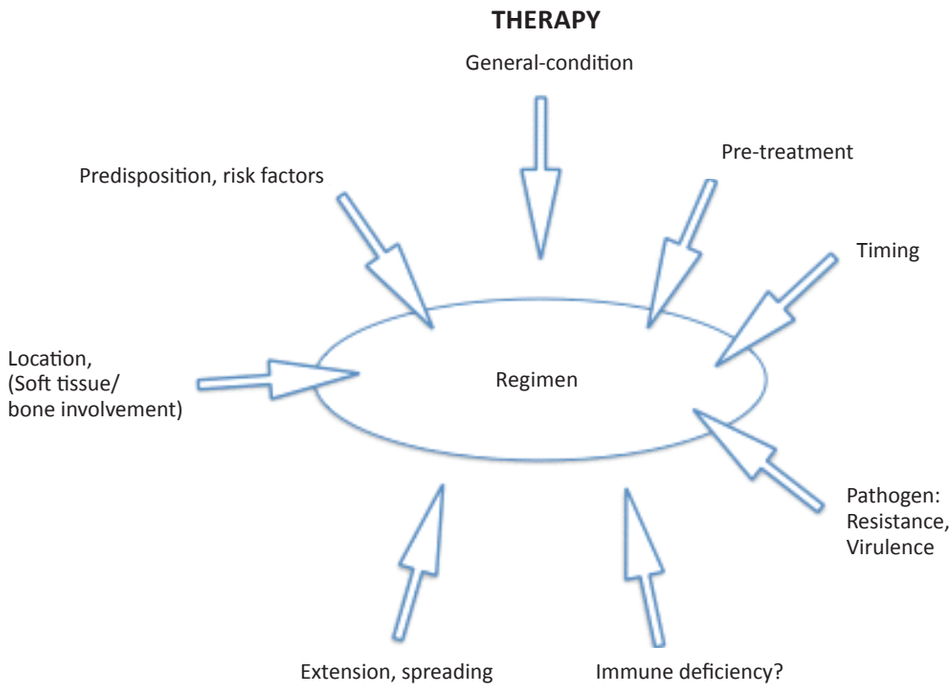

Figure 1. Many factors influence decisions in the therapy of an infected elbow arthroplasty.

of early infection (Marculescu *et al.* 2006). A jet-lavage system with disinfectants (e.g. Lavanid) and extensive cleansing using Ringers solution of at least 5 liters is recommended (Hudek and Gohlke 2013). The polyethylene inlays and if present, bushings should be exchanged (Hudek and Gohlke 2013). Multiple big drains should be applied before wound closure. A systemic antibiotic regimen selected in compliance with the observed bacterial resistances should be administered for 3–6 months. In most cases a combination therapy including Rifampicin is applied because of its bio-film penetrating capabilities.

The success rate of early debridement and antibiotic therapy was reported to be 65% after > 2 years in a study of 27 infected elbow arthroplasties (Achermann *et al.* 2011). Patients were treated with Ciprofloxacin and Rifampicin for 3 months while the first 2 weeks were administered i.v. (Achermann *et al.* 2011).

In cases of chronic infections a one stage or a two-stage revision has to be evaluated. In a single stage revision concept reported by Gille *et al.* (2006) the joint was aspirated preoperatively in order to search for the germ. Then, after debridement and implant removal, a new prosthesis was introduced using bone cement loaded with antibiotics. Five of six reported cases were found free of infection after a mean follow up of 6 years (Gille *et al.* 2006).

In a two stage revision an articulating spacer loaded with antibiotics is implanted after implant removal and debridement (Hudek and Gohlke 2013). This method has several advantages; troublesome bacteria can be addressed more effectively because all foreign bodies are removed including the bacterial bio-films. Seating of the new implant is often better to perform because the preoperative planning can be based on CT scans without metallic artefacts. This is particularly important when bony defects are present. The downside of a two-stage revision is the necessity of two operations. The mobilization process is often delayed which can lead to stiffness and a longer

rehabilitation period. Further, it is a demanding technique with a long learning curve. However, the cement spacer loaded with antibiotics will elude them locally in a high concentration and leave the systemic concentration of antibiotics low. The spacer further seals cancellous bone and thereby blood loss is reduced. If unusual bacteria (gram negative) were found during the first operation, in a two-stage revision there is a second chance to eliminate the germ in the second operation. If possible, an articulating design should be preferred (Hudek and Gohlke 2013). It helps to prevent contractions due to unbalanced soft tissues. With the articulating design early mobilization is possible in most cases, which dramatically improves the implantation of the new prosthesis.

The literature reports a high success rate in two stage revisions in elbow arthroplasty ranging between 78–98% (Schwyzer *et al.* 1998; Yamaguchi *et al.* 1998; Wolfe *et al.* 1990). In an own series of 9 chronically infected elbow arthroplasties we observed no revision in all patients after a mean follow-up of 3,4 years. In 5 of these 9 cases more than two different bacterial species were observed.

Before the operation, the complete implant including the cement mantle/plug have to be fully assessed on radiographs (Figure 2).

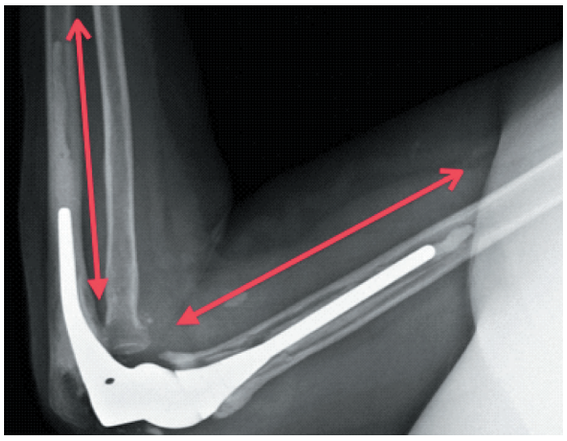

Figure 2. The complete prosthesis in shown including the cement mantle on a radiograph. It is important to obtain images that are long enough to assess the length of the prosthesis with the end of the cement mantle and cement plugs. This helps to perform the osteotomy for implant removal.

As a first step in a dorsal approach to the elbow, the ulnar nerve is prepared and placed into a safe position (Figure 3).

Then, the implant and the entire cement mantle have to be removed over osteotomies that are long enough to expose the complete shaft on the humeral and ulnar side. The ulna is particularly thin in its distal part, which makes it very difficult to establish osteotomies that are big enough on the one hand to remove the implant and on the other, still leave enough bone to close the bony window (Figure 4). When all options for sufficient implant fixation fail custom made implants will become necessary. The custom implant has to be designed upon CT scans which can be performed with reduced signal artifacts when the articulating spacer is implanted.

Discussion

In cases of massive bone defects, strut allografts can be wrapped around the implant (Foulkes and Mitsunaga 1993). The complications in elbow revision arthroplasty are commonly attributed to extensor mechanism deficiency. Thin soft tissues, triceps insufficiency, osteolysis or avulsion of the

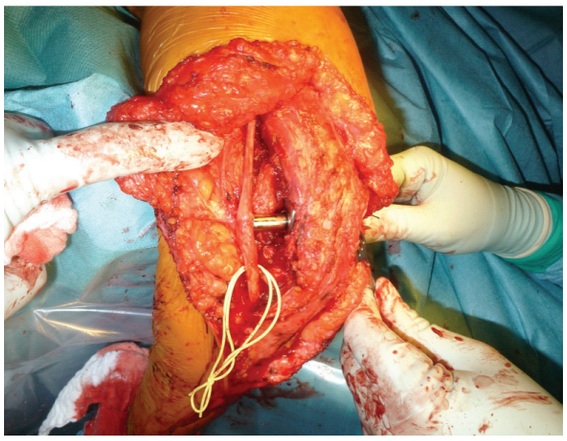

Figure 3. The ulnar nerve is prepared and saved during further surgery. The nerve can be entrapped in scar tissue, which makes the initial liberation a critical step.

olecranon, low-grade infections or failures of Achilles tendon allograft are frequently observed (Schwyzer *et al.* 1998; Yamaguchi *et al.* 1998; Thillemann *et al.* 2006; Throckmortonet al. 2010).

of systemic antibiotics show reliable results. Because bacterial bio-films are of great concern in prosthetic infections, complete removal of all foreign bodies including bone cement is mandatory in every revision

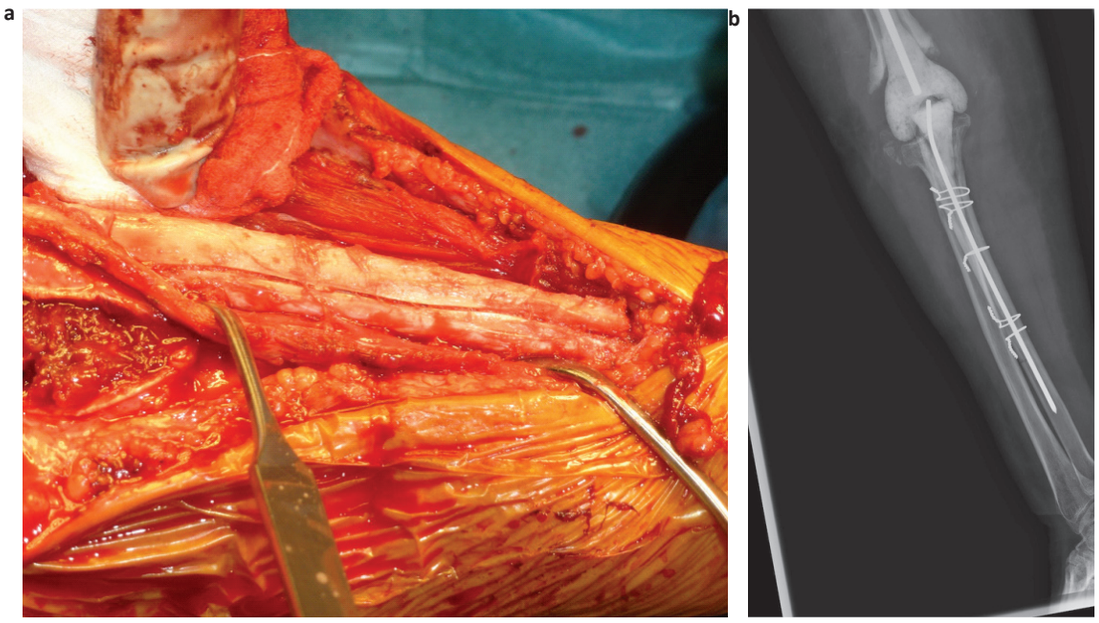

Figure 4. (a) An osteotomy of the ulna creates a bony window in order to remove the stem including the cement mantle. (b) Articulating spacer with wire cerclages around the ulna. The bony window has been replaced and compressed with the cerclages. For the second operation, the wires can be left in place and only the spacer will be removed.

Conclusions

In summary, revision of infected elbow arthroplasties is demanding for the patient and the surgeon. A two-stage procedure using an articulating spacer loaded with antibiotics in combination with the use case. The postsurgical antibiotics regimen should be collaborated with infectiologists in order to provide effective and save drug combinations.

REFERENCES

Achermann Y., Vogt M., Spormann C., Kolling C., Remschmidt C., Wust J., Trampuz A. *Characteristics and outcome of 27 elbow periprosthetic joint infections: results from a 14-year cohort study of 358 elbow prostheses*. Clinical Microbiology and Infection 2011; 17, 3: 432–438.

Achermann Y., Sahin F., Schwyzer H.K., Kolling C., Wust J., Vogt M. *Characteristics and outcome of 16 periprosthetic shoulder joint infections*. Infection 2013; 41, 3: 613–620.

Bruggemann H. *Insights in the pathogenic potential of Propionibacterium acnes from its complete genome*. Seminars in Cutaneous Medicine and Surgery 2005; 24, 2: 67–72.

Bruggemann H., Lomholt H.B., Kilian M. *The flexible gene pool of Propionibacterium acnes*. Mobile Genetic Elements 2012; 2, 3: 145–148.

Fevang B.T., Lie S.A., Havelin L.I., Skredderstuen A., Furnes O. *Results after 562 total elbow replacements: a report from the Norwegian Arthroplasty Register.* Journal of Shoulder and Elbow Surgery 2009; 18, 3: 449–456.

Fischer N., Mak T.N., Shinohara D.B., Sfanos K.S., Meyer T.F., Bruggemann H. *Deciphering the Intracellular Fate of Propionibacterium acnes in Macrophages*. BioMed Research International 2013;2013:603046.

Foulkes G.D., Mitsunaga M.M. *Allograft salvage of failed total elbow arthroplasty. A report of two cases*. Clinical Orthopaedics and Related Research 1993; 296: 113–117.

Gille J., Ince A., Gonzalez O., Katzer A., Loehr J.F. *Single-stage revision of peri-prosthetic infection following total elbow replacement*. Journal of Bone and Joint Surgery. British Volume 2006; 88, 10: 1341–1346.

Gschwend N., Simmen B.R., Matejovsky Z. *Late complications in elbow arthroplasty*. Journal of Shoulder and Elbow Surgery 1996; 5(2 Pt 1): 86–96.

Hudek R., Gohlke F. *Endoprosthesis infections of the shoulder: diagnosis and therapy algorithm*. Der Orthopäde 2013; 42, 7: 552–559.

Hudek R., Sommer F., Kerwat M., *Abdelkawi A.F., Loos F., Gohlke F. Propionibacterium acnes in shoulder surgery: true infection, contamination, or commensal of the deep tissue?* Journal of Shoulder and Elbow Surgery 2014; 23, 12: 1763–1771.

Hudek R., Sommer F., Abdelkawi A.F., Kerwat M., Muller H.H., Gohlke F. *Propionibacterium acnes in shoulder surgery: is loss of hair protective for infection?* Journal of Shoulder and Elbow Surgery 2016: S1058-2746(15)00589-3. doi: 10.1016/j.jse.2015.10.018. (Epub ahead of print)

Levy O., Iyer S., Atoun E., Peter N., Hous N., Cash D., Narvani A.A. *Propionibacterium acnes: an underestimated etiology in the pathogenesis of osteoarthritis?* Journal of Shoulder and Elbow Surgery 2013; 22, 4: 505–511.

Marculescu C.E., Berbari E.F., Hanssen A.D., Steckelberg J.M., Harmsen S.W., Mandrekar J.N., Osmon D.R. *Outcome of prosthetic joint infections treated with debridement and retention of components.* Clinical Infectious Diseases 2006; 42, 4: 471–478.

Mastrokalos D.S., Zahos K.A., Korres D., Soucacos P.N. *Arthroscopic debridement and irrigation of periprosthetic total elbow infection.* Arthroscopy 2006; 22, 10: 1140 e1141–1143.

Plaschke H.C., Thillemann T.M., Brorson S., Olsen B.S. *Implant survival after total elbow arthroplasty: a retrospective study of 324 procedures performed from 1980 to 2008*. Journal of Shoulder and Elbow Surgery 2014; 23, 6: 829–836.

Schwyzer H.K., Gschwend N., Loehr J., Simmen B. *Die Alloarthroplastik des Ellbogengelenkes.* Operative Orthopädie und Traumatologie 1998; 10, 1: 10–25.

Sethi P.M., Sabetta J.R., Stuek S.J., Horine S.V., Vadasdi K.B., Greene R.T., Cunningham J.G., Miller S.R. *Presence of Propionibacterium acnes in primary shoulder arthroscopy: results of aspiration and*

tissue cultures. Journal of Shoulder and Elbow Surgery 2015; 24, 5:796–803.
Thillemann T.M., Olsen B.S., Johannsen H.V., Sojbjerg J.O. *Long-term results with the Kudo type 3 total elbow arthroplasty.* Journal of Shoulder and Elbow Surgery 2006; 15, 4: 495–499.
Throckmorton T., Zarkadas P., Sanchez--Sotelo J., **Morrey B.** *Failure patterns after linked semiconstrained total elbow arthroplasty for posttraumatic arthritis.* The Journal of Bone and Joint Surgery. American Volume 2010; 92, 6: 1432–1441.
Trampuz A., Osmon D.R., Hanssen A.D., Steckelberg J.M., Patel R. *Molecular and antibiofilm approaches to prosthetic joint infection.* Clinical Orthopaedics and Related Research 2003; 414: 69–88.
Voloshin I., Schippert D.W., Kakar S., Kaye E.K., Morrey B.F. *Complications of total elbow replacement: a systematic review.* Journal of Shoulder and Elbow Surgery 2011; 20, 1: 158–168.
Wolfe S.W., Figgie M.P., Inglis A.E., Bohn W.W., Ranawat C.S. *Management of infection about total elbow prostheses.* The Journal of Bone and Joint Surgery. American Volume 1990; 72, 2: 198–212.
Yamaguchi K., Adams R.A., Morrey B.F. *Infection after total elbow arthroplasty.* The Journal of Bone and Joint Surgery. American Volume 1998; 80, 4: 481–491.

Authors reported no source of funding.
Authors declared no conflict of interest.

Author responsible for correspondence:
Robert Hudek
Rhön Klinikum AG
Klinik für Schulter- und Ellbogenchirurgie
Salzburger Leite 1
97616 Bad Neustadt, Germany
robert@hudek.de

Autorzy nie zgłosili źródła finansowania.
Autorzy nie deklarowali konfliktu interesów.

Autor odpowiedzialny za korespondencję:
Robert Hudek
Rhön Klinikum AG
Klinik für Schulter- und Ellbogenchirurgie
Salzburger Leite 1
97616 Bad Neustadt, Niemcy
robert@hudek.de