

Bespalchuk A., Volotovski A. Implementation of bilhaut procedure in management of preaxial hand polydactyly. *Issue Rehabil. Orthop. Neurophysiol. Sport Promot.* 2017; 18: 34–38. DOI: 10.19271/IRONS-00032–2017–18

IMPLEMENTATION OF BILHAUT PROCEDURE IN MANAGEMENT OF PREAXIAL HAND POLYDACTYLY

Andrey Bespalchuk

Alexey Volotovski

Department of Traumatology and Orthopaedics, Belarusian State Medical University, Minsk, Belarus

SUMMARY

Thumb polydactyly is the most common type of polydactyly in the hand. There is a variety of surgical procedures for the treatment. The aim of this study is assessment of the effectiveness of Bilhaut procedure and its modifications in hand surgery.

Keywords: polydactyly, thumb duplication, Bilhaute-Cloquet procedure

Date received: 15th December 2016

Date accepted: 22nd February 2017

Introduction

Preaxial polydactyly is the most common congenital malformation of the hand. It is characterized by a typical duplication of the first hand ray. The prevalence of this condition is 8 cases in 100.000 newborns (Grünert 1999).

Wessel's classification for preaxial polydactyly is commonly used. It defines seven types of polydactyly, basing on duplication of a certain finger segment. Thumb duplication is a serious condition accompanied in most cases by a certain degree of hypoplasia and may include either collateral ligament deficiencies, abnormal extrinsic tendon anatomy, soft tissue abnormalities are often present (Flat 1994).

There is a variety of surgical procedures for that problem. In case of normally formed one of the thumbs, resection of residual

ZASTOSOWANIE METODY LECZENIA WEDŁUG BILHAUT W LECZENIU WRODZONEGO KCIUKA DODATKOWEGO

Andrey Bespalchuk

Alexey Volotovski

Department of Traumatology and Orthopaedics, Belarusian State Medical University, Minsk, Białoruś

STRESZCZENIE

Najczęściej rozpoznawana polidaktylia dotyczy dodatkowego palca po stronie kciuka. Znane są różne techniki operacyjne. Celem tego badania jest ocena skuteczności operacji wg Bilhaut i jego modyfikacji w praktyce.

Słowa kluczowe: polidaktylia, zdwojenie kciuka, metoda leczenia według Bilhaut-Cloquet

Data otrzymania: 15 grudnia 2016

Data zaakceptowania: 22 luty 2017

finger is acceptable. If indicated it should be followed by deformity correction through the osteotomy and ligament reconstruction (Patel *et al.* 2013). Still, this approach can't be used in cases of severe dysplasia or hypoplasia of both thumbs, since it cannot lead to a satisfactory anatomical and functional outcome (Ogino *et al.* 1996; Larsen and Nicolai 2005).

Bilhaut first reported his alternative approach to reconstruction of Wessell's type I–II polydactyly method at French Surgical Congress in 1889. Surgical procedure was based on distal dysplastic counter phalanx marginal resection followed by alignment and formation of a new phalanx.

Later on, an extended Bilhaut procedure, known as Bilhaut-Cloquet method, used for preaxial deformities type III–IV, was

reported. In case of duplication of both distal and proximal phalanxes of a thumb incisions are performed from palmar and dorsal sides. Both distal and proximal phalanxes are resected; coaptation of residual fragment and a nail bed reconstruction is performed. Wires are used for osteosynthesis (Tonkin and Bulstrode, 2007).

Aim

Assessment of effectiveness of Bilhaut procedure and its modifications in hand surgery is an aim of this survey-study.

Material and methods

Nineteen patients in 6 years period (including 2016) were surgically treated with implementation of Bilhaut procedure principals at Republican Hand Surgery Center (Minsk Clinical Hospital #6). The procedure was performed for 14 male and 5 female patients in the age group from 6 month to 2 years of age.

According to Wessel's classification, type II was diagnosed in 7 cases, type III in 1 case, type IV in 10 cases and type VII in 1 case.

Original Bilhaut procedure was performed in 7 cases. Resection of thumb hypoplastic distal counter phalanxes was performed. After that, coaptation of the tufts was performed in the manner providing their matching. Kirschner wires were used for osteosynthesis. Special attention was given to coaptation of nail beds. Nail bed was sutured with Prolen nidle 5-0 or 6-0. Taking in consideration little age of the patients in postoperative period immobilization of wrist, forearm, and elbow was done for 4–5 weeks. Stitches were removed on day 14. After cast removal, wires were extracted and active exercises were initiated aimed on increasing of amplitude of movements in thumb joints.

Original Bilhaut-Cloquet procedure was performed in 4 cases. Z-incision was used on both dorsal and palmar sides of a duplicated finger. After that longitudinal osteotomy of distal and proximal phalanxes were performed. Inner fragments were evacuated.

Tendon resection of a one part of duplicated tendon of flexor pollicis longus muscle was performed in 2 cases. At this stage coaptation of distal and proximal tufts was performed followed by osteosynthesis with Kirschner wires or transossal sutures. The adjustment was controlled both visual and on X-ray. Suturing of dorsal aponeurosis was done. Wound was closed in layers. Additional attention was given in the course of operation to a fine alignment of fragment in area of articulating surfaces. Aftercare included upper limb immobilization with a portable cast splint. Sutures were removed on day 14. 5–6 weeks later wires were removed after X-ray control and a course of physiotherapy initiated.

As an alternative to Bilhaut-Cloquet procedure, its two-stage modification was suggested in 4 cases. At the first stage of procedure a surgical syndactyly of hypoplastic fingers was performed. Three months later, at the second stage the rest of the procedure similar to the described above was done solely from the dorsal incision. In the course of procedure, palmar neuro-vascular bundles and tendons were not disturbed.

Shortening of one proximal phalanx due to the difference in length in three cases Wessel's type IV preaxial polydactyly cases (two patients) and Wessel's type VII (one patient) in addition to Bilhaut-Cloquet procedure was done. In one case type VII polydactyly resection of additional middle phalanx was performed.

In one case, Wessel's type IV polydactyly severely affected one distal phalanx and it was completely resected while the rest of the procedure was typically completed.

On early stages of our implementation of Bilhaut-Cloquet procedure Kirschner wires were used for osteosynthesis. Now we give preference to ligature fixation of bone fragments. After reposition of proximal phalanxes transossal absorbable 3-0 ligatures were placed through the channels preliminary made at the same level with Kirschner wires 0.6 mm in diameter and tired (Figures 1 and

2). This was enough for fixation of proximal phalange fragments.

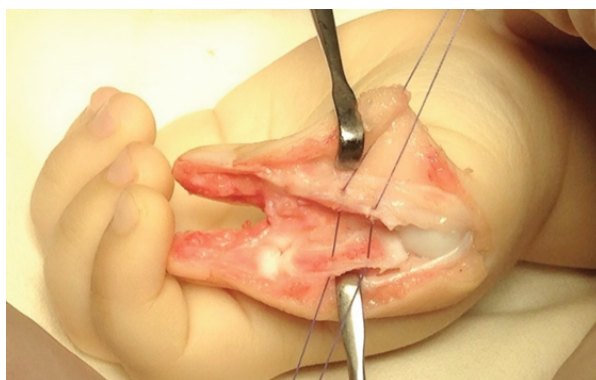


Figure 1. Transosseous osteosynthesis due to absorbable ligature fixation.

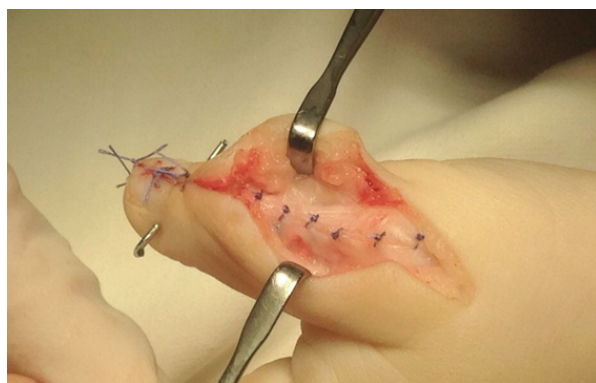

Figure 2. Suture of a dorsal aponeurosis.

Results

There was observed edge necrosis of palmar skin flap of a newly-formed thumb in one patient after standard Bilhaut-Cloquet procedure with wire fixation of proximal phalanx tufts. This complication was caused by an excessive skin tension in the wound due to inadequate skin excision and postoperative oedema. Nevertheless, the wound healed via secondary intention and it did not affect long-term result. No other complications in postop were detected.

Long-term results were scrutinized in the period from six month to six years postop.

The functional and esthetic outcome was assessed by parents with the help of visual analog scale in the range of results: “perfect”, “good”, “satisfactory” and “unsatisfactory” in percentage. In addition amplitude of active and passive movement

in MCP and IP joints was measured and X-ray was performed (Figure 3).

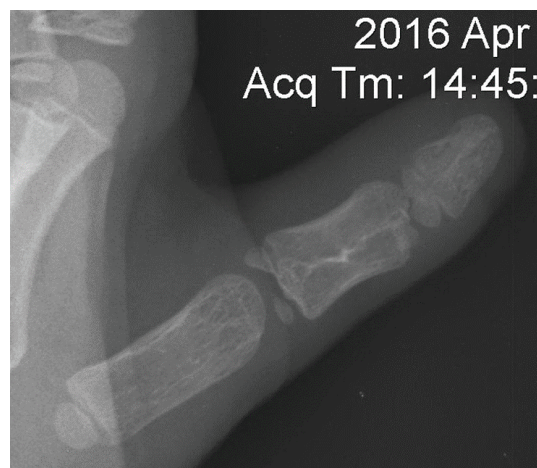

Figure 3. X-ray examination after two-stage modification of Bilhaut-Cloquet procedure (follow up 5-years).

Result was “perfect” in 8 cases, “good” in 10 cases and “satisfactory” in one case. No “unsatisfactory” results were obtained.

The best movement amplitude in IP joint with “minimally limited” to “not limited” result was achieved in standard Bilhaut procedure (in type II). In Bilhaut-Cloquet procedure (III, IV, VII type) almost in all cases IP joint was restricted in a different degree.

Almost all patients had a dorsal linear thickening (scar-associated) on a nail plate without significant cosmetic defect. In some cases this line was barely visible (Figure 4).

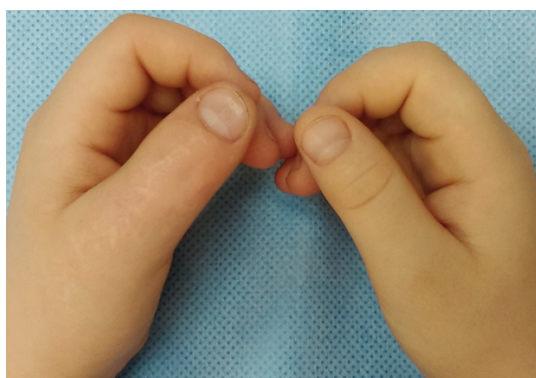

Figure 4. Aesthetic outcome after two-stage modification of Bilhaut-Cloquet procedure (follow up 5-years).

Discussion

There is a variety of surgical procedures used for treatment of duplicated thumb.

Practical clinical interest is focused on preaxial polydactyly associated with high-grade hypoplasia, including cases with deformity at the level of MCP and IP joints.

As known, simple removal of the additional finger-thumb is not enough and in many cases leads to residual deformity. As a rule, such surgeries cause postop zigzag deformity, which can be hardly corrected later (He and Nah 2016).

The advantage of Bilhaut-Cloquet procedure over ablation with reconstruction is two-fold. First, this procedure allows for the recreation of a thumb of near-normal size from two hypoplastic components since precise amount can be taken from each thumb for reconstruction. Second, since the collateral ligaments are not violated during the central wedge resection, stability of the IP and MCP joints is maintained, which is

important in pinch and grip functions (Guo *et al.* 2013).

Basing on our practical experience matching of congruence in joint junctions' surfaces is a crucial point for further functional outcome. Removal of a duplicated part of a flexor pollicis longus tendon did not show any difference in the outcome.

We modified Bilhaut-Cloquet procedure into two stages, when at the first stage only the skin was excised and the syndactyly was achieved by suturing counter fragments together. Three months later the second stage was done from the dorsal incision with the performance of a core stage of Bilhaut-Cloquet procedure. This type of operation we implemented to avoid the necrotic complications. The benefit of this method is that it avoids interference into palmar neuro-vascular bundles. Thus, the risk of postop complications was minimized.

In our practice we used both Kirchner wires and transossal absorbable sutures for osteosynthesis of repositioned tufts and found sutures to be more practical in use. It is based on the fact that transossal sutures provide stable tuft fixation, simplify postop management, and avoid manipulations for wires or other transossal fixators' removal.

Conclusions

Bilhaut procedure and its modifications in case of dysplastic and hypoplastic finger duplications is a procedure of choice. This type of procedure leads to appropriate functional cosmetic outcomes.

Modified two-stage Bilhaut-Cloquet procedure can be used as an alternative to the classical one.

REFERENCES

- Flatt, A.** (1994) *"The care of congenital hand anomalies."* Ch.7: Extra thumb, Quality Medical Publishing, Inc., Second Edition, pp. 120–145.
- Grünert, J.** (1999) *"Congenital malformation of the hand."* British Journal of Hand Therapy, 4(3), pp. 93–99.
- Guo, B., Lee, S.K., Paksima, N.** (2013) *"Polydactyly."* Bulletin of the Hospital for Joint Diseases, 71(1), pp. 17–23.
- He, B., Nan, G.** (2016) *"Causes of secondary deformity after surgery to correct Wassel type IV-D thumb duplication."* Journal of Hand Surgery, 41E(7), pp. 739–744.
- Larsen, M., Nicolai, J.P.A.** (2005) *"Long-term follow-up of surgical treatment for thumb duplication."* The Journal of Hand Surgery, 30B(3), pp. 276–281.
- Ogino, T., Ishii, S., Takahata, S., Kato, H.** (1996) *"Long-term results of surgical treatment of thumb polydactyly."* Journal of Hand Surgery, 21A, pp. 478–486.
- Patel, A.U.C., Tonkin, M.A., Smith, B.J., Alshehri, A.H., Lawson, R.D.** (2013) *"Factors affecting surgical results of Wassel type IV thumb duplications."* Journal of Hand Surgery, 39E(9), pp. 934–943.
- Tonkin, M.A., Bulstrode, N.M.** (2007) *"The Bilhaut-Cloquet procedure for Wassel types II, IV and VII thumb duplication."* Journal of Hand Surgery, 32E(6), pp. 684–693.

*Authors reported no source of funding.
Authors declared no conflict of interest.*

*Author responsible for correspondence:
Andrey Bepalchuk
Department of traumatology and orthopaedics

Belarusian State Medical University, Minsk,
Belarus
bepalchuk@gmail.com*

*Autorzy nie zgłosili źródła finansowania.
Autorzy nie deklarowali konfliktu interesów.*

*Autor odpowiedzialny za korespondencję:
Andrey Bepalchuk
Department of Traumatology and Orthopaedics

Belarusian State Medical University, Minsk,
Białoruś
bepalchuk@gmail.com*