

Sycheuski L., Audzeichyk P., Hmelenko A., Anosov V. New approach in nuss minimally invasive procedure for treatment of pectus excavatum. *Issue Rehabil. Orthop. Neurophysiol. Sport Promot.* 2017; 18: 15–24. DOI: 10.19271/IRONS-00030-2017-18

NEW APPROACH IN NUSS MINIMALLY INVASIVE PROCEDURE FOR TREATMENT OF PECTUS EXCAVATUM

Leanid Sycheuski¹

Pavel Audzeichyk¹

Alexandr Hmelenko¹

Viktor Anosov²

¹Grodno Regional Clinical Children's Hospital, Grodno, Belarus

²Grodno State Medical University, Grodno, Belarus

SUMMARY

Introduction

The pectus excavatum is the most frequent pathology of chest wall. The Nuss minimally invasive procedure for pectus excavatum correction has become the gold standard for treatment of this pathology.

Aim

Describing the new surgical procedure and evaluation of the results of pectus excavatum treatment with modified Nuss technique.

Materials and methods

From September 2014 to June 2016, 22 patients (age range 11–17 years) with pectus excavatum underwent the surgical correction with new standardized and reproducible innovation technic using thoracoscopy, special sternum elevation maneuver, retrosternal metal and silicone introducers, own designed instruments and retrosternal fixator with stabilizers.

Results

Results of 22 patients treatment operated in our clinic since 2014 with the use of the modified Nuss procedure were evaluated. The mean operation time was reduced from 95 ± 22 to 47 ± 8 minutes. The excellent result was achieved in 19 patients (89%)

NOWE PODEJŚCIE W LECZENIU KLATKI PIERSIOWEJ LEJKOWATEJ MAŁOINWAZYJNĄ METODĄ NUSS

Leanid Sycheuski¹

Pavel Audzeichyk¹

Alexandr Hmelenko¹

Viktor Anosov²

¹Grodzieński Regionalny Szpital Kliniczny Dziecięcy, Grodno, Białoruś

²Państwowy Uniwersytet Medyczny, Grodno, Białoruś

STRESZCZENIE

Wstęp

Lejkowata deformacja jest najczęściej spotykaną patologią klatki piersiowej, a złotym standardem jej korekcji jest operacja metodą Nuss.

Cel

Ocena wyniku leczenia klatki piersiowej lejkowatej zmodyfikowaną przez nas metodą Nuss i opisanie nowej techniki wykonywania zabiegu operacyjnego.

Materiał i metody

W okresie od września 2014 do czerwca 2016 operowano 22 pacjentów (w wieku od 11 do 17 lat) z kłatką piersiową lejkowatą. Zabieg wykonywano zmodyfikowaną metodą Nuss z torakoskopią, nowym implantem i zestawem instrumentarium.

Wyniki

Średni czas zabiegu został zmniejszony z 95 ± 22 do 47 ± 8 minut w porównaniu z klasyczną techniką Nussa. Bardzo dobry wynik osiągnięto u 19 pacjentów (89%), średni wzrost FEV1 wyniósł 13,84%, a wzrost FVC 11%. Jeden pacjent został operowany

with a mean increase of FEV1 with 13.8%, and FVC with 11%. One reoperation for fixator displacement had occurred. Two patients remained with the slight chest asymmetry. One patient had intraoperative bleeding from internal thoracic vein, which has been successfully stopped using thoroscopic coagulation.

Conclusion

The use of our modified Nuss procedure has significantly reduced the surgery time, minimized intraoperative trauma, reduced intraoperative risks and allowed to achieve good clinical results.

Keywords: pectus excavatum, Nuss procedure, thoracoscopy

Date received: 18th December 2016

Date accepted: 23rd February 2017

Introduction

Pectus excavatum (PE), also known as “funnel chest”, is the most frequent anterior thoracic deformity. The rate of occurrence of this malformation is ranged from 1 out of 1000 newborns to 1 out of 400 newborns (Ravitch 1966). Pathology is often accompanied by changes of the thoracic organs (heart, lungs, mediastinum), associated with compression and dislocation due to the reduction of the distance between the sternum and spine. Conservative treatment is ineffective. The overall goal of surgical treatment is the correction of the deformity according to physiological and cosmetic indications. The latter is extremely important in adolescents, where the appearance of the breasts can cause significant problems in social adaptation and low self-esteem. Thus, the patient’s desire to correct the deficiency may be an indication for surgical treatment by itself.

Minimally invasive method of correction of pectus excavatum, described by Nuss and his colleagues in 1998 (Nuss *et al.* 1998) has become the gold standard of treatment

powtórnie z powodu przemieszczenia implantu. U dwóch pacjentów powstała nieznaczna asymetria klatki piersiowej. Jeden z pacjentów miał śródoperacyjne krwawienie z żyły śródpiersiowej, które zatrzymano za pomocą koagulacji torakoskopowej.

Wnioski

Stosowanie zmodyfikowanej nami metody Nuss znacznie redukuje czas zabiegu, zmniejsza uraz tkanek podczas operacji i znacznie polepsza wyniki leczenia.

Słowa kluczowe: klatka piersiowa lejkowata, procedura Nuss, torakoskopia

Data otrzymania: 18 grudnia 2016

Data zaakceptowania: 23 luty 2017

for patients with this pathology. Nuss technique significantly exceeds the traditional “open” procedure due to minimal surgical trauma without costal cartilage resection (Hebra *et al.* 2000, Nuss *et al.* 2002). Recent studies have shown a high degree of satisfaction with the results thoracic wall deformity correction using the Nuss procedure (90%) (Hebra *et al.* 2000). The Nuss procedure changed the surgical treatment of the patients with PE from an open operation with a sternotomy to a minimal invasive operation with two small lateral incisions on the chest.

However, because the sheath passes through the restricted space between the heart and the sternum depressed, the technique carries the risk of complications, ranging from minor to life-threatening levels. Approximately 10 cases of cardiac perforations (two of them fatal) are described in the literature. True cases (not covered) undoubtedly much more (Moss *et al.* 2001, Castellani *et al.* 2008, Bouchard *et al.* 2009, Tedde *et al.* 2011, Becmeur *et al.* 2011).

In this regard, since 2001, thoracoscopic assisted minimally invasive thoracoplasty has performed in many clinics. This reduced the risk of lungs and the pericardium perforation (Bufo and Stone 2001, Croitoru *et al.* 2002, Zallen and Glick 2004).

Stable retrosternal bar fixation in the postoperative period after the deformation correction largely determines long-term results (Nuss *et al.* 2002, Croitoru *et al.* 2002). Migration and rotating of implanted bar in the classical method of fixing (pericostal) reach up to 20% (Hebra *et al.* 2000, Uemura 2003). It is unclear why, but little effort of researchers and practitioners have been aimed at creating a standardized simple and convenient method of fixing retrosternal design to the chest. The only construction that was invented in the history of Nuss method is a lateral stabilizer. And, although the stabilizer is largely solved the problem of the migration structure, reducing it to 5.3% (Hebra *et al.* 2000) all species (terminal stabilizer, claw fixator, hinge plate, multipoint fixation technique) have a number of disadvantages. Most of them require additional costal fixation, which is accompanied by the risk of intercostal vessels and nerves damage, pleura, lung, pericardium and heart penetration and extend the time of surgery. A cosmetic and mechanical discomfort, subcutaneous bursitis, seroma, abrasions and sores accompany junction incongruence between retrosternal fixator and chest wall (structure superimposed on each other).

Aim

To describe and evaluate the pectus excavatum treatment results with facilitating Nuss techniques and creating standardized reproducible procedure which includes:

1. thoracoscopy application;
2. safe sternum elevating technique;
3. silicone introducer applying for the retrosternal plate installation;
4. usage of the own designed simple and convenient instruments and implants.

Material and methods

From April 2002 to June 2014, twenty patients with pectus excavatum underwent the traditional Nuss procedure at Grodno Regional Clinical Children's Hospital, Grodno, Belarus (age range 4–20 years).

From September 2014 to October 2016, twenty two patients (age range 11–17 years) with PE underwent surgical correction with new standardized reproducible technical innovation using thoracoscopy, special sternum elevation technique, retrosternal metal and silicone introducers, own designed instruments and retrosternal bar with stabilizers and instrument set (Figures 1 and 2). The indications for surgery were symptomatic (cardiac or respiratory impairment in 5 patients) and cosmetic and cosmetic-related psychological (in 17 patients) problems and Haller index greater than 3.25. We also recommended operative treatment when the Haller index was 3.25 and less only in children with severe cosmetic and cosmetic-related psychological problems, because most of the patients had an asthenic habitus and a narrow anterior-posterior chest diameter. There were 17 males and 5 females, and the preoperative computed tomography (CT) scan showed the mean Haller index (4.2 ± 0.86) from 2.55 to 6.39.

For deformity correction, retrosternal titanium bar and stabilizers of our own design "Medbiotech" was used. The distinctive feature of our bar design is terminal stabilizers, fastened by a "dovetail" and locked by submerged screws.

Operation technique

The pectus bar fixator is prepared preoperatively. The length of the bar should be measured from the midaxillary line in one side to the opposite midaxillary line minus 1–2 cm length. The bar is bent from the center out to either end with the bar bender, tilter and shaped to fit each individual patient's chest.



Figure 1. Retrosternal fixator, stabilizers and submerged screws.

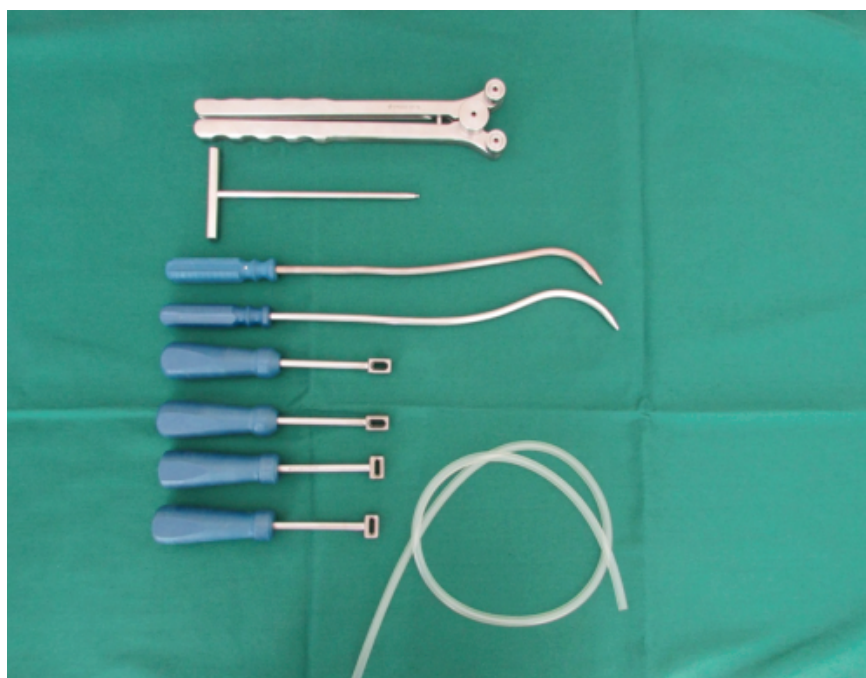


Figure 2. Bar bender, introducers, tilters, silicone tube.

The patient is placed in the supine position with both arms abducted at the shoulders.

The landmark of chest is performed with a sterile marking pen in the deepest portion of the pectus on the corresponding intercostal spaces on the right and left sides where the bar is to be inserted, and on the points on the pectus ridge that correspond to the horizontal plane from the deepest point of the pectus to the lateral chest wall incisions.

A longitudinal 4-cm skin incision is made on the midaxillary line at the level of the skin marks. A skin tunnel is raised anteriorly from both incisions to the top of the pectus ridge at the previously selected intercostal

space at the edge of the sternum on the top of excavation.

A 5-mm blunt trocar is inserted 1–2 intercostal spaces below the space that has been chosen for the pectus bar on the patient's right side. With 30° thoracoscope pleural cavity, lung, and mediastinal structures now is visualized. Controlled ventilation by the anesthesiologist with small tidal volumes is limited to lung expansion and provides good thoracoscopic visualization of vital structures.

In cases of severe depression of sternum and rigid chest (usually in 15–18 years old patients) two small incisions, one intercostal space above the space ridge at

the previously selected intercostal space at the edge of the sternum are performed. Inserted bone forceps grasped the sternum and elevated it (Figure 3).

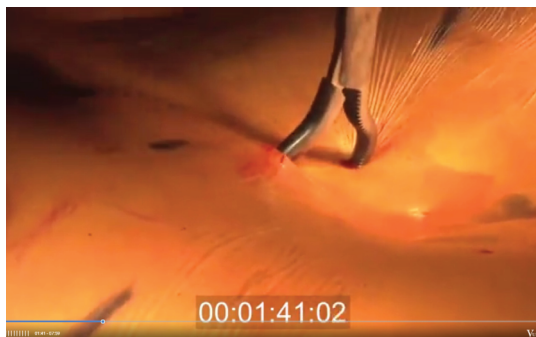

Figure 3. Sternum elevation.

pull up with bone forceps (in severe cases) the sternum is forcefully lifted.

Once the introducer is passed behind the sternum, the tip is pushed through the intercostal space at the top of the pectus ridge on the left side and brought out through the opposite skin incision. One side of silicone suction connecting tube (22 mm-diameter and 30–40 cm-long) is spindled onto the introducer tip and the other side is connected to the right end of the prepared pectus bar. The introducer is pulled backward from left to right, followed by the tube, creating a canal for the bar to pass with the concave side up (Figure 4).

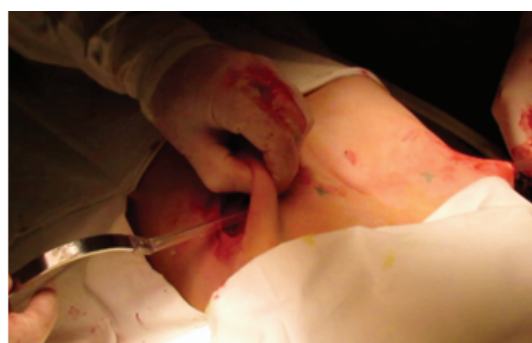
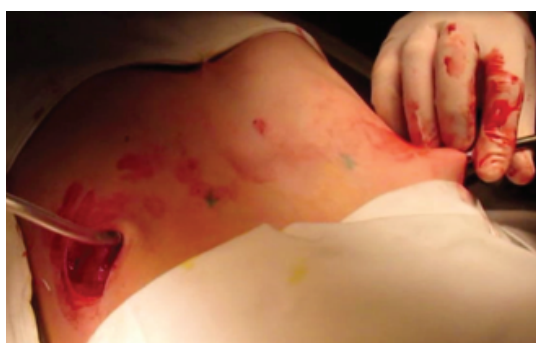
Figure 4. Retrosternal bar drawing with silicone suction connecting tube.

The skin incisions are elevated and previously marked the intercostal space at the edge of the sternum is identified. The pectus introducer with conical tip is inserted under the sternum in this point, slowly advanced across the anterior mediastinal space immediately under the sternum with careful videoscopic guidance. As the instrument is passed to the contralateral side and sternum

Stabilizers with the dovetail slots were connected congruent ends of bar and fixed with submerged screws. A nonabsorbable thread is passed through stabilizers holes. Using pectus bar rotational instruments (bar tilters) the bar is rotated 180 degrees around its long axis, thus elevate the sternum (Figure 5). The ends of the bars were placed under the muscle fascia and sutured

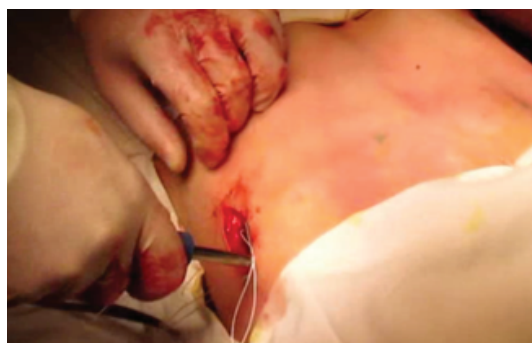
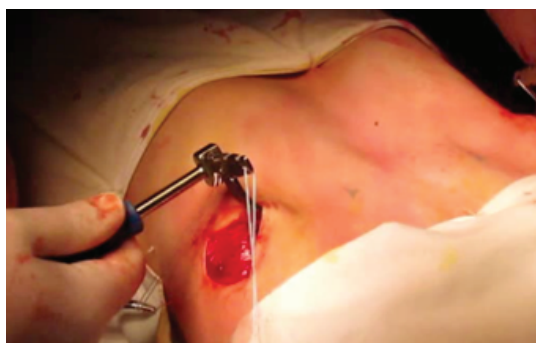
Figure 5. Rotating maneuver with bar tilters.

with previously passed threads under muscle-fascia complex without pericostal sutures. After the blade's stabilization and wounds closure, the evacuation of the pneumothorax from the left or right hemithorax is made thoracoscopically during its extraction and lung ventilation with positive pressure.

Results

No fatal injury or damage to underlying cardiac structures occurred. One bleeding complication occurred. Internal thoracic vein was damaged by introducer. But the problem was resolved immediately and successfully by arthroscopic coagulation and suction. In the videoassisted group, operated after 2014, no pneumothorax occurred. The operating time (after anesthesia) in this group ranged from 25 to 65 min. ($46,6 \pm 8,1$ min., $n = 22$); and the hospital stay ranged from 10 to 12 days

of bar migration and no recurrence occurred in group operated after 2014. The previous complaints of chest pain, poor exercise tolerance and repeated upper respiratory infections in group operated after 2014 according symptomatic indications did not recur. Pneumothorax in post-op period was observed in 12 patients operated before 2014 and no pneumothorax was observed in patients operated after 2014. Thirteen patients operated with new technique underwent lung function tests preoperatively, as well as 3–12 months postoperatively. The results showed an improvement of lung function tests, with a mean FEV1 increase of 13.84%, and FVC increase of 11%.

The bar was removed with no surgical or postoperative complications in 3 patients, with the results remaining constant and the implant remaining in place a mean 20 months (range, 18–24) (Figure 6.).

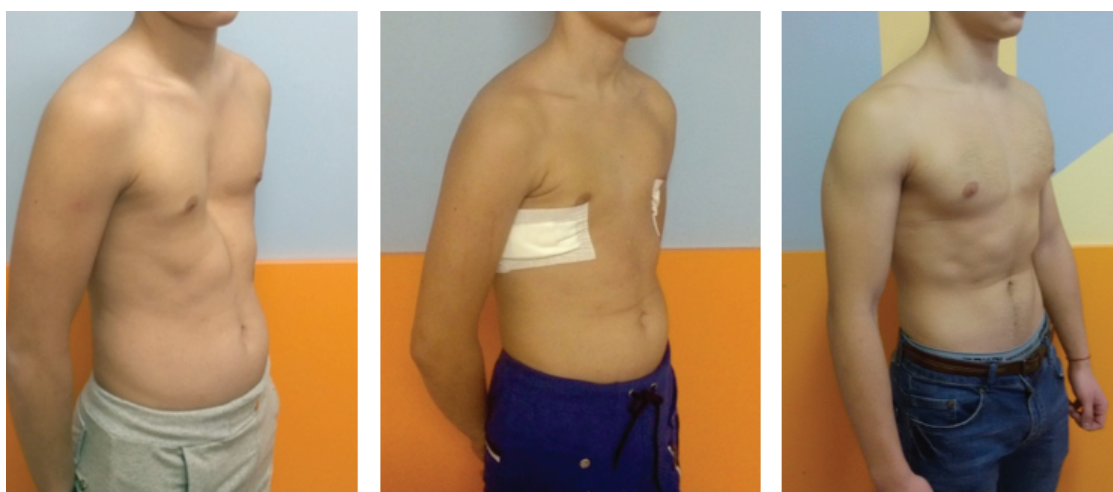

Figure 6. Patient with pectus excavatum before surgery, after operation, 1 year after bar removal.

(10.4 ± 1.5 days, $n = 22$). In the traditional Nuss group without arthroscopic videoassistance, the operating time ranged from 50 to 150 min. (94.5 ± 22.4 min, $n = 20$) and the hospital stay was in the range of 11–18 days (12.8 ± 2.6 days, $n = 20$). There was one case of bar displacement and one recurrence of the funnel chest deformity after traditional Nuss procedure without arthroscopic videoassistance and one case

Satisfaction results of operative treatment of patients in the group operated after 2014 is represented in Figure 7.

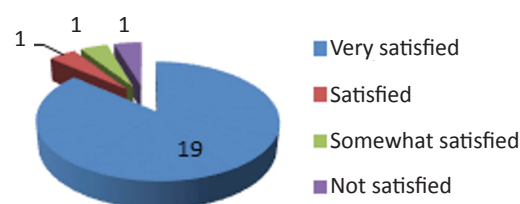


Figure 7. Personal satisfaction degree.

Discussion

The surgical treatment of pectus excavatum has changed in the last few decades. When a thoracoscope is used in the Nuss procedure, it certainly benefits in visualizing ensuring that vital vascular structures are not injured during the insertion of the dissector. Park and co-workers reports (Marusch and Gastinger 2003, Park *et al.* 2004, Leonhardt *et al.* 2005, Gips *et al.* 2008) reviewed the complications associated with the Nuss procedure and suggested that risk of pericardium and even heart injuries and other complications would increase without the thoracoscopic guidance. Technical innovation using thoracoscope and bone forceps elevation of the sternum reduces the risk of cardiac injury. Bone forceps opens the anterior mediastinum space effectively and makes the following dissection relatively safe and straightforward.

In the original report of Nuss the introducer was inserted into the thoracic cavity and a way through the mediastinum was achieved by gently swinging its tip. Once the introducer had emerged through the left intercostal space, two umbilical tapes were tied to its tip and passed through the created substernal tunnel in the opposite direction (Nuss *et al.* 1998). These tapes served as traction to move, from right to left, in this tunnel. This kind of passage can be quite difficult and sometimes can become dangerous, especially when fat tissue is found in the anterior mediastinum or bars with notched ends are used. Banever and colleagues has reported major complication during a bar passage – right internal mammary laceration during this maneuver (Banever *et al.* 2003). The technique of bar installation retrosternally presented in this study is very simple. This procedure accomplished smoothly and easily in a few seconds and can be repeated as many times as needed: for example, when we realize that bar is too short or too long and for example incorrectly bended. A silicone tube is deemed useful for covering the bar end,

thus avoiding any possibility of lacerating the mediastinal fat and vessels during the operative procedure.

Among the complications, bar dislocation and migration is a major problem in minimally invasive PE repair performed using a pectus bar, with reported bar dislocation rates of 5% to 20% based on early experiences. As a major effort to overcome this serious problem, the stabilizer was developed. This decreased the bar dislocation rate to approximately 5%. Although use of pericostal fixation sutures was effective, we believed that we could improve the safety, technical simplicity, and reproducibility of the technique without pericostal suturing. Suturing can cause internal organ injuries such as lung puncture and subsequent pneumothorax, even when performed by experienced surgeons, and more serious problems, such as cardiac puncture with disastrous internal bleeding, have occurred. Moreover, pericostal suturing takes a operation time (10–20 minute). Our clinical data suggests that the pericostal suturing can be avoided in most cases when bilateral stabilization is done. In most patients, using bilateral bar stabilizers with only muscle-fascia suturing is feasible, safe, and at least as effective as pericostal suture in preventing bar displacement, but more convenient and quick to use. In our series, 1 reoperation for bar displacement occurred. Dove-tail bar-stabilizer is congruous, snap-lock together in easy way and latched with the submerged screw. The devices are palpable beneath the skin along with the pectus bar, but they are significantly lower profile than the conventional stabilizer and generally cause little discomfort to the patients.

Therefore, compared with the standard Nuss procedure, in the patients in our series the operating time and the postoperative hospital stay was significantly reduced. Patients can be discharged from the hospital within 10 days without any drugs. Pectus bars were maintained for 2 years. As the final step of the procedure, pectus bar was

removed in 3 cases (15%). After bar removal all patients had excellent results and maintained a normal form of chest. Achieved correction was durable in all patients who had bar removal during the follow-up period of up to 1 year. Our technique using a titanium fixator and stabilizers with the dovetail slots and submerged screws, silicone tube and bone forceps improves pectus bar stability, safety, and ease of use. We significantly reduced bar dislocation rate and complications by using our next-generation approach with the new devices.

After 22 Nuss procedures performed by our approach we can state that this method has its benefits: minimally invasive surgery, reduced operating time, minimal blood loss, fast social and professional reinstatement, as well as improved lung ventilatory function with excellent aesthetic long term results. As it can be seen, pectus excavatum does not have only aesthetic repercussions, it also has physiological involvement. As a consequence of these factors we consider that the surgical intervention is essential regarding the ventilatory lung function improvement as well as the aesthetic improvement (Figure 7). Comparing the results in the literature with ours we can state that the Nuss procedure is an effective method with elegant cosmetic results, low percentage of complications and excellent improvement in cardiopulmonary status with fast social and professional reintegration (Leonhardt *et al.* 2005, Kim *et al.* 2005, Krasopoulos *et al.* 2006, Kelly *et al.* 2008, Nuss 2008, Castellani *et al.* 2008, Vegunta *et al.* 2008, Fonkalsrud 2009).

In our study, after analyzing all the patients, we observed that patient's satisfaction degree is excellent in over 95% of cases – this completely justifies the surgical approach for this condition. Modifications of the original method help to decrease the complication rate.

Conclusions

Our technique using a titanium fixator and dovetail stabilizers, silicone tube and bone

forceps improves pectus bar stability, safety, and simplifies the procedure. We extremely reduced bar dislocation and complications rate by using our next-generation approach with the new fixator and instrument set. Using our standardized technical approach to minimally invasive procedure D. Nuss has significantly reduced the time of surgery, tissue trauma, intraoperative risks and achieves good clinical and cosmetic results.

REFERENCES

- Banever, G.T., Tashjian, D.B., Moriarty, K.P., Konefal, S.H.** (2003) 'The Nuss procedure: our experience from the first fifty'. *Pediatr Endosurg Innov Tech.*, 7, pp. 261–267.
- Becmeur, F., Ferreira, C.G., Haecker, F.M., Schneider, A., Lacreuse, I.** (2011) 'Pectus excavatum repair according to Nuss: is it safe to place a retrosternal bar by a transpleural approach, under thoracoscopic vision'. *J Laparoendosc Adv Surg Tech., A* 21, pp. 757–761.
- Bouchard, S., Hong, A.R., Gilchrist, B.F., Kuenzler, K.A.** (2009) 'Catastrophic cardiac injuries encountered during the minimally invasive repair of pectus excavatum'. *Semin Pediatr Surg.*, 18, pp. 66–72.
- Bufo, A.J., Stone, M.M.** (2001) 'Addition of thoracoscopy to Nuss pectus excavatum repair'. *Pediatr Endosurg Innovative Tech.*, 5 (2), pp. 159–162.
- Castellani, C., Schalamon, J., Saxena, A.K., Hoellwarth, M.E.** (2008) 'Early complications of the Nuss procedure for pectus excavatum a prospective study'. *Pediatr Surg Int.*, 24, pp. 659–666.
- Croitoru, D.P., Kelly, R.E., Goretsky, M.J., et al.** (2002) 'Experience and modification update for the minimally invasive Nuss technique for pectus excavatum repair in 303 patients'. *J Pediatr Surg.*, 37, pp. 437–45.
- Fonkalsrud, E.W.** (2009) '912 open pectus excavatum repairs: changing trends, lessons learned: one surgeon's experience'. *World J Surg.*, 33 (2), pp. 180–190.
- Gips, H., Zaitsev, K., Hiss, J.** (2008) 'Cardiac perforation by a pectus bar after surgical correction of pectus excavatum: case report and review of the literature'. *Pediatr Surg Int.*, 24, pp. 617–620.
- Hebra, A., Swoveland, B., Egbert, M., et al.** (2000) 'Outcome analysis of minimally invasive repair of pectus excavatum: Review of 251 cases'. *J Pediatr Surg.*, 35, pp. 252–257, discussion, pp. 257–258.
- Kelly, R.E. Jr, Cash, T.F., Shamberger, R.C. et al.** (2008) 'Surgical repair of pectus excavatum markedly improves body image and perceived ability for physical activity: multicenter study'. *Pediatrics*, 122 (6), pp. 1218–1222.
- Kim, D.H., Hwang, J.J., Lee, M.K. et al.** (2005) 'Analysis of the Nuss procedure for pectus excavatum in different age groups'. *Ann Thorac Surg.*, 80 (3), pp. 1073–1077.
- Krasopoulos, G., Dusmet, M., Ladas, G., Goldstraw, P.** (2006) 'Nuss procedure improves the quality of life in young male adults with pectus excavatum deformity'. *Eur J Cardiothorac Surg.*, 29(1), pp. 1–5.
- Leonhardt, J., Kubler, J.F., Feiter, J., Ure, B.M., Petersen, C.** (2005) 'Complications of the minimally invasive repair of pectus excavatum'. *J Pediatr Surg.*, 40, pp. 7–9.
- Marusch, F., Gastinger, I.** (2003) 'Life-threatening complication of the Nuss procedure for funnel chest. A case report'. *Zentralbl Chir.*, 128, pp. 981–998.
- Moss, R.L., Albanese, C.T., Reynolds, M.** (2001) 'Major complications after minimally invasive repair of pectus excavatum: case reports'. *J Pediatr Surg.*, 36, pp. 155–158.
- Nuss, D., Kelly, R.E., Croitoru, D.P., et al.** (1998) 'A 10-year review of minimally invasive technique for the correction of pectus excavatum repair'. *J Pediatr Surg.*, 33, pp. 545–552.
- Nuss, D., Croitoru, D.P., Kelly, R.E., et al.** (2002) 'Review and discussion of the complications of minimally invasive pectus excavatum repair'. *Eur J Pediatr Surg.*, 12, pp. 230–234.
- Nuss, D.** (2008) 'Minimally invasive surgical repair of pectus excavatum'. *Semin Pediatr Surg.*, 17 (3), pp. 209–217.
- Park, H.J., Lee, S.Y., Lee, C.S.** (2004) 'Complications associated with the Nuss procedure: analysis of risk factors and suggested measures for prevention of complications'. *J Pediatr Surg.*, 39, pp. 391–395.
- Ravitch, M.M.** (1966) 'Atypical deformities of the chest wall – absence and deformities of the ribs and costal cartilages'. *Surgery*, 59(3), pp. 438–449.
- Tedde, M.L., Campos, J.R., Das-Neves-Pereira, J.C., Abrao, F.C., Jatene, F.B.** (2011)

'The search for stability: bar displacement in three series of pectus excavatum patients treated with the Nuss technique'. Clinics, 66, pp. 1743–1746.

Uemura, S., Nakagawa, Y., Yoshida, A., Choda, Y. (2003) *'Experience in 100 cases with the Nuss procedure using a technique for stabilization of the pectus bar'.* Pediatr Surg Int., (19), pp. 186–189.

Vegunta, R.K., Pacheco, P.E., Wallace, L.J., Pearl, R.H. (2008) *'Complications associated with the Nuss procedure: continued evolution of the learning curve'.* Am J Surg., 195 (3), pp. 313–316, discussion pp. 316–317.

Zallen, G.S., Glick, P.L. (2004) *'Miniature access pectus excavatum repair: lessons we have learned'.* J Pediatr Surg., 39 (5), pp. 685–689.

*Authors reported no source of funding.
Authors declared no conflict of interest.*

*Autorzy nie zgłosili źródła finansowania.
Autorzy nie deklarowali konfliktu interesów*

*Author responsible for correspondence:
Leanid Sycheuski
Grodno Regional Clinical Children's Hospital,
Grodno, Belarus
Ul. Ostrovski 22,
230029 Grodno, Belarus
leosych@gmail.com*

*Autor odpowiedzialny za korespondencję:
Leanid Sycheuski
Grodzieński Regionalny Szpital Kliniczny
Dziecięcy, Grodno, Białoruś
Ul. Ostrowskiego 22,
230029 Grodno, Białoruś
leosych@gmail.com*