

Mikhovich M., Hlazkin L. *Early Results of Single-Event Multilevel Surgery in Treatment of Children with Cerebral Palsy. Issue Rehabil. Orthop. Neurophysiol. Sport Promot.* 2018; 25: 67–75. DOI: 10.19271/IRONS-000080–2018–25.

EARLY RESULTS OF SINGLE-EVENT MULTILEVEL SURGERY IN TREATMENT OF CHILDREN WITH CEREBRAL PALSY

Mikhail Mikhovich

Leanid Hlazkin

Mogilev Regional Children's Hospital, Belarus

SUMMARY

Introduction

Cerebral palsy is a group of permanent disorders of the development of movement and posture, causing activity limitation, that are attributed to non-progressive disturbances that occurred in the developing fetal or infant brain. In recent decades most surgeons began to use Single-Event Multilevel Surgery – SEMLS for correction limb deformities.

Aim

The aim of our study was to evaluate the early results of SEMLS, performed in Orthopaedic Department of the Mogilev Regional Children's Hospital.

Materials and methods

The early results of SEMLS in 36 children with cerebral palsy, operated in 2014–2017 were studied. The goals of treatment were different depending on the group by Gross Motor Function Classification System (GMFCS). For 36 children performed 251 procedures. Observation Gate Scale (OGS) was used to determine effectiveness of treatment.

Results

The main early results were determined after 12–24 months. In the group of patients GMFCS 2–3 the average improvement by the OGS was 7.2 points, GMFCS 4–7 points. Parents of patients GMFCS 5 reported an improvement in care after surgery.

WCZESNE WYNIKI ZABIEGU CHIRURGII WIELOPOZIOMOWEJ W LECZENIU DZIECI Z MÓZGOWYM PORĄŻENIEM DZIECIĘCYM

Mikhail Mikhovich

Leanid Hlazkin

Mogilev Regional Children's Hospital, Białoruś

STRESZCZENIE

Wstęp

Porażenie mózgowe to grupa trwałych zaburzeń rozwoju ruchu i postawy, powodująca ograniczenie aktywności, które przypisuje się niepostępującym zaburzeniom występującym w rozwijającym się mózgu płodu lub niemowlęcia. W ostatnich dziesięcioleciach większość chirurgów zaczęła stosować zabieg chirurgii wielopoziomowej – SEMLS.

Cel

Celem naszych badań była ocena wczesnych wyników SEMLS przeprowadzonych w Oddziale Ortopedycznym Regionalnego Szpitala Dziecięcego w Mohylewie (Białoruś).

Materiał i metody

Przeanalizowano wczesne wyniki SEMLS u 36 dzieci z mózgowym porażeniem dziecięcym, przeprowadzonych w latach 2014–2017. Cele leczenia różniły się w zależności od grupy za pomocą systemu klasyfikacji funkcji GMFCS. Dla 36 dzieci wykonano 251 zabiegów. Skala obserwacji chodu (OGS – Observation Gate Scale) została wykorzystana do określenia skuteczności leczenia.

Wyniki

Główne wyniki wczesnego leczenia zostały ustalone po 12–24 miesiącach. W grupie pacjentów GMFCS 2–3, średnia poprawa zweryfikowana OGS wynosiła 7,2 punktów, dla GMFCS 4–7 punktów. Rodzice chorych z GMFCS 5 odnotowali poprawę pooperacyjną.

Conclusions

For the child with cerebral palsy the main goals of surgical treatment included improving the child's motor activity and elimination of severe limb deformities. SEMLS changes the whole pathological stereotype of musculoskeletal balance of extremities. It can improve the child's motor activity, eliminate the severe contractures of joints and provide adequate care for him in a relatively short period of time.

Keywords: Cerebral Palsy, Single-Event Multilevel Surgery, Musculoskeletal Balance of Extremities, Limb Deformities, Observation Gate Scale.

Date received: 19th February 2018

Date accepted: 18th March 2018

Introduction

Cerebral palsy (CP) is a group of permanent disorders of the development of movement and posture, causing activity limitation, that are attributed to non-progressive disturbances that occurred in the developing fetal or infant brain (O'Shea, 2008). It was first described by William Little in 1861 (Little, 1861–62). Besides the disorders of movement child with CP often have sensory deficit, equilibrium deficiencies, mental retardation, epileptic strokes, reduced eye sight and secondary progressive muscle-bone disorders. These include: muscle-tendon contractures, torsional and angular bone deformities and instability of joints, up to dislocations. The conservative methods of treatment include: orthotics, various methods of physical therapy and mechanotherapy, the use of botulinum toxin and administration of drugs with antispastic effect. Despite the certain effectiveness of conservative treatment, surgical correction of limb deformities is used in most cases of cerebral palsy.

Single orthopedic procedures for the treatment of musculoskeletal pathology in children with CP have been known for more than a hundred years. Stage surgical

Wnioski

Dla dziecka z porażeniem mózgowym główne cele leczenia chirurgicznego spowodowały poprawę aktywności motorycznej dziecka i eliminację ciężkich deformacji kończyn. SEMLS zmienia cały patologiczny stereotyp równowagi mięśniowo-szkieletowej kończyn, może poprawić aktywność ruchową dziecka, wyeliminować ciężkie przykurcze stawów i zapewnić odpowiednią opiekę w stosunkowo krótkim czasie.

Słowa kluczowe: Porażenie mózgowe, Zabicie wielopoziomowej chirurgii, Równowaga mięśniowo-szkieletowa kończyn, Deformacje kończyn, Skala obserwacji chodu

Data otrzymania: 19 luty 2018

Data zaakceptowania: 18 marca 2018

correction was previously performed separately at different levels of the limbs (hips, knees, ankles). Norlin and Tkaczuk called this approach «Birthday Syndrome», associating each Birthday with a new operation and a new cast (Norlin and Tkaczuk, 1985). Long-term immobilization resulted in muscle atrophy and required long-term rehabilitation.

In recent decades the tactics of surgical treatment of cerebral palsy was changed significantly. Most surgeons began to use Single-Event Multilevel Surgery – SEMLS (Figure 1). This approach is based on the simultaneous performing of all necessary orthopedic procedures at various limb levels by two operating teams (Rang, 1990). Soft tissue procedures and bone osteotomies are performed at the same time.

Aim

The aim of our study was to evaluate the early results of SEMLS, performed in Orthopaedic Department of the Mogilev Regional Children's Hospital.

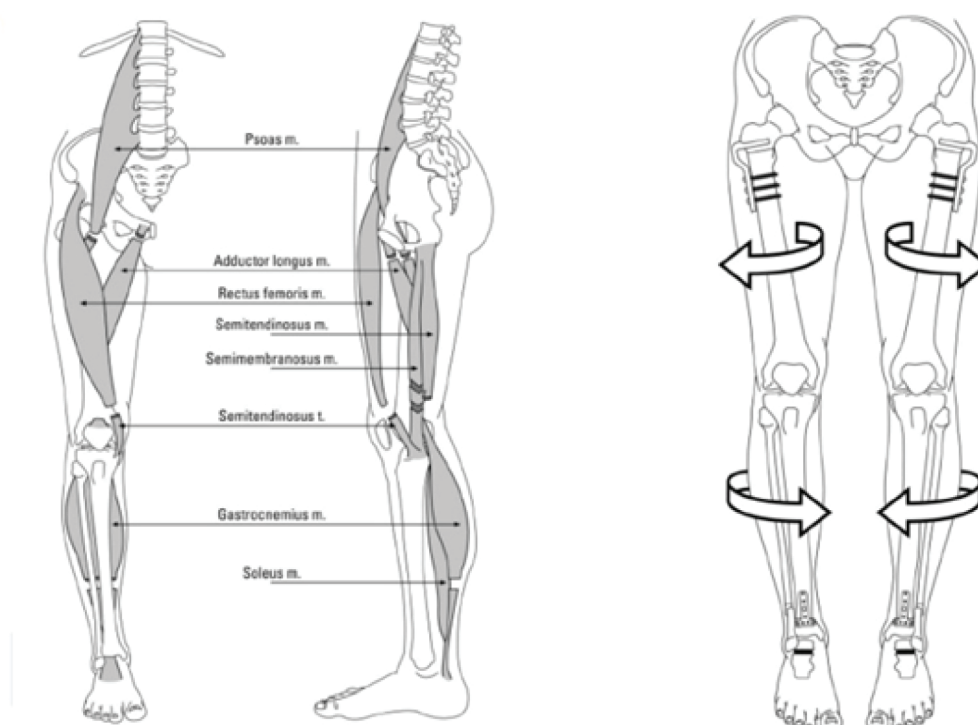


Figure 1. Simultaneous performing of the soft tissue procedures and bone osteotomies during SEMLS (Thomason *et al.*, 2014).

Materials and methods

The early results of SEMLS in 36 children operated in 2014–2017 were studied. These patients accounted for 35% of children operated for spastic lower limbs deformities in this period of time. The determining factor of this procedure was the simultaneous performing of at least 2 operations at different levels of the lower limbs (McGinley, 2012). The mean age at the time of surgery was 7, 8 years; the youngest child was 3, the oldest – 18. Nine patients had surgery by Ulzibat technique previously. The remaining were treated conservatively for a long time without significant improvement. 14 patients had mental retardation in varying degrees.

The goals of treatment were different depending on the group by Gross Motor Function Classification System (GMFCS). In severe spastic diplegia (GMFCS 4) the main intention was to teach children to walk, at least with the help of aids. In milder forms (GMFCS 2–3) – improve the gait and self-service. With spastic tetraparesis (GMFCS 5) the surgery was aimed at facilitation

of a child care and the creation of the possibility of moving in a wheelchair (Figure 2).

Each patient was determined according to the level of central nervous system damage before surgery. Twenty-three patients presented spastic diplegia, 13 – spastic tetraparesis.

The active and passive range of motions in hip, knee and ankle were determined. Specific tests were used for measure the spasticity of the separate muscle groups: Thomas for iliopsoas muscle, Duncan-Ely – rectus femoris, Phelps – gracilis and Silverskold test showed involvement of gastrocnemius muscle.

The gait of the patient was videotaped in normal mode and in the slow motion mode for determine the degree of flexion or recurvation in the knee during stance phase and the order of foot parts loading in the different phases of the gait.

All information was scored and recorded in «Observation Gate Scale» (OGS). Each patient was classified according to GMFCS. X-Ray of the hips for the measurement of the

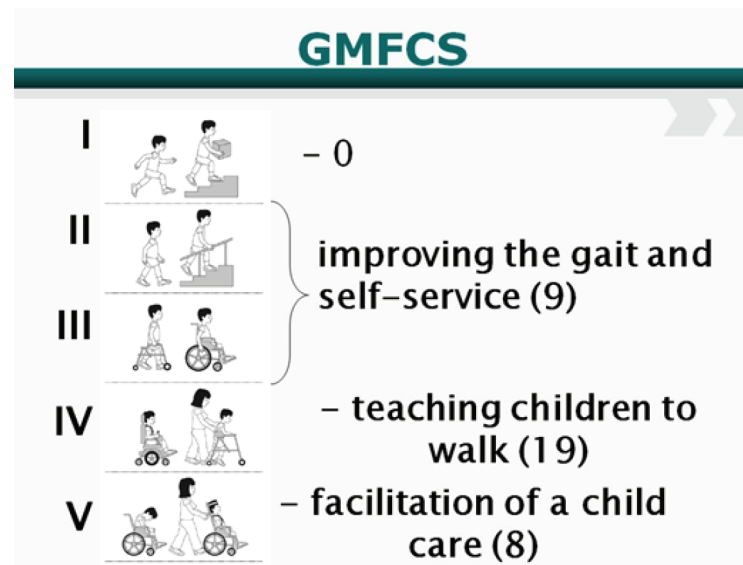


Figure 2. The goals of surgical treatment and number of patients in different groups. (Modified from illustration of Reid *et al.*, The Royal Children's Hospital Melbourne)

migration index by Reimers» was performed for all children (Reimers, 1980). Complete blood count, blood chemistry, blood clotting test, ABO blood group test, urinalysis, ECG and pediatrician examination were included in preoperative preparing. All operations were performed under regional anesthesia with intravenous sedation by two surgical teams with two operating nurses. For 36 children there were performed 251 procedures (Table 1).

Almost all patients underwent adductor release. From the transverse incision, 2cm distal to the inguinal fold, adductor longus and gracilis muscles were identified and transected. If necessary, especially in GMFCS 5, the operation was expanded by the anterior branch of the obturatorius nerve resection and the transection of the adductor magnus muscle. The procedure was performed from the same approach and was aimed at eliminating the recurrence

Table 1. Number and type of surgeries.

Surgery	Amount
Adductor release	53
Lengthening of the medial hamstrings	45
Strayer procedure	43
Intrapelvic lengthening of the iliopsoas muscle	32
Subspinal tendotomy and rectus femoris muscle lengthening	24
Adductor release with anterior branch of the obturatorius nerve resection	9
Proximal varus hip osteotomy	7
Lengthening of the peroneus muscles	6
Iliopsoas muscle release	6
Calcaneal lengthening osteotomy by Evans	5
Achilles tendon lengthening	5
Achilles tendon ventralization	4
Foot medial arch plastic	3

Table 1. (cont.) Number and type of surgeries.

Surgery	Amount
Anterior branch of the obturatorius nerve resection	2
Proximal valgus hip osteotomy by Shanz	2
Rectus femoris to sartorius transfer	2
Peroneus longus transfer to the medial surface of the foot	2
Split anterior tibialis transfer	1
Total	251

of the adduction contracture, preventing dislocation of the hips and facilitating the care of the patient.

Sixteen patients underwent intrapelvic iliopsoas muscle lengthening in order to eliminate the flexion contracture of the hips. Approach was made from the parallel to the iliac crest incision, slightly medial to the spina iliaca anterior superior. The tendinous part of the iliopsoas muscle transected. In case of the positive Duncan-Ely test, subspinal tendomyotomy and lengthening of the rectus femoris muscle were performed from the same approach. If the patient had no the perspective of independent movement, the tendon of the iliopsoas muscle was released from the lesser trochanter of the hip using the approach as for adductor release.

Lengthening of the hamstrings was performed in 23 patients. Popliteal angle more than 60 degrees was an indication for surgery. From the longitudinal internal incision, 4 cm proximally to the popliteal fold, the gracilis tenotomy, the fractional lengthening of the semimembranosus and the lengthening of the semitendinosus tendon were performed.

Rectus femoris to sartorius transfer used to treat patients with stiff-knee gait and positive Duncan-Ely test. An incision was made superior to the proximal pole of the patella. The rectus femoris was dissected off the underlying vastus intermedius, divided transversely just proximal to the superior pole of the patella, passed medially and sewn into the sartorius muscle.

Strayer procedure was performed to eliminate equinus in 23 patients in case

of positive Silverskold test. From the posterior longitudinal incision at the level of the gastrocnemius muscular to tendinous part transition the latter was separated and transected. In the case of the negative Silverskold test, the Achilles tendon was lengthened according to the technique of Moreau and Lake (1987). The ventralization of the Achilles tendon also was performed according to the Sychevsky technique. The tendon was cut from its origin using the transverse incision along the posterior surface of the foot, then shifted ventrally and sewn to the heel bone by the transsosal sutures (Sychevskij, 2008).

In the patients with plano-valgus foot deformities the lengthening osteotomy of the calcaneus by Evans was made, usually with simultaneous soft-tissue medial arch of the foot plastic. From lateral approach to the calcaneus transverse osteotomy was performed at the level of sinus tarsi. Trapezoidal allograft was placed into the zone of osteotomy and fixed with a pin, catching the heel-cube joint. The tendon of the posterior tibialis muscle was shortened from medial approach. Percutaneous lengthening of the peroneus longus muscle was performed in case of pronounced its contracture. Peroneus longus transfer to the medial surface of the foot was made in 1 patient with significant valgus foot deformity.

In one case the split anterior tibialis transfer to 4 metatarsal bone was used to eliminate the varus deformity of the foot. The origin of the tendon to the first sphenoid bone was located, the tendon was split into 2 parts in the coronal plane, the lateral part

was subcutaneously transferred and sewed to the 4 metatarsal bone.

The proximal varus hip osteotomy was performed to eliminate the subluxation of the hips, it was performed according to the open-wedge technique, filling of the defect with a cortical allograft. Fixation was made by plate with screws.

One patient (GMFCS 5), already having long lasting high bilateral hip dislocations, underwent the proximal valgus hip osteotomy by Shanz to remove the pain syndrome and facilitate care.

Long leg splints immobilization with abduction of hips about 30 degrees, extension of the knees and 90 degrees of foot dorsiflexion was used after surgery. Short leg cast was used in case of Evans osteotomy. Rehabilitation began next day after operation. The initial goal was to teach the child to stand and walk in the splints. Splints were removed 2–3 weeks after the operation. Then orthoses were made and rehabilitation was continued (Figure 3).

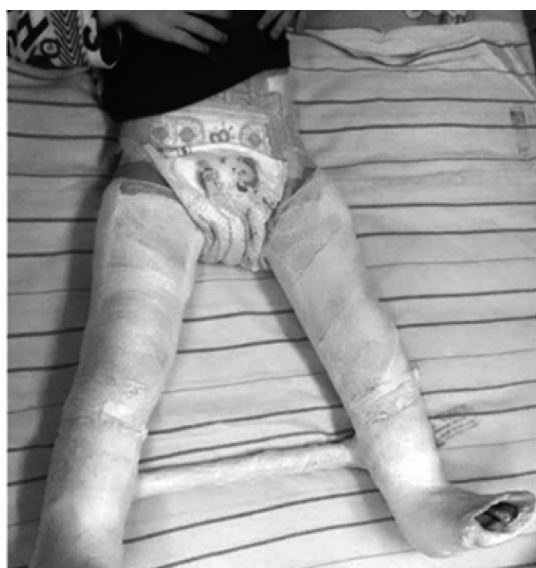

Figure 3. The principles of immobilization – long leg splints.

The mean points of improvement by OGS was used to determine the effectiveness of treatment.

Results

The results of surgery began to be studied immediately after the removal of splints (2–3 weeks after operation). The main early results were determined after 12–24 months. At the same time, if necessary, additional corrections were planned.

In the group of patients GMFCS 2–3 (9 patients), the average improvement by the OGS was 7.2 points. The best result is an improvement by 11 points, the worst – improvement by 2 points. Two patients improved GMFCS III to II.

In the group of patients GMFCS 4 (19 patients), the average improvement by the OGS was 7 points. The best result was an improvement by 14 points, the worst – improvement by 2 points. 4 patients improved GMFCS IV to III, two patients IV to II.

One patient from this group, despite the adductor release with anterior branch of the obturatorius nerve resection, performed at the age of 3 years, has pronounced hip adduction contracture. That fact can be an indication for selective dorsal rhizotomy or implantation of the baclofen pump.

Parents of 8 patients GMFCS 5 reported an improvement in care after surgery. During follow up deterioration was not observed.

Discussion

In the literature, some authors pointed to the effectiveness of Single-Event Multilevel Surgery in cerebral palsy. So, for example, Godwin in his study in 84 patients showed that the functional class of GMFCS can change after performing SEMLS (Godwin *et al.*, 2009). Our study results also confirmed the possibility of changing the GMFCS to the side of improvement after surgical treatment. Thomason in a study of 19 patients showed stable improvement in gait and function in children for 1 year, 2 years and 5 years after SEMLS (Thomason *et al.*, 2013). McGinley conducted a survey of 31 SEMLS efficacy trials in 2011 and found that an improvement of the range of motions was found in 8 of them, and an improvement in the

kinematic parameters in 16. 2 studies revealed an increase in the GMFCS, and in 4 GMFCS remained unchanged (McGinley, 2012). Despite the fact that in our study we used other system for measure the effectiveness of treatment, the results indicate a significant improvement in function of most patients in the early period of observation.

Conclusions

Brain disorders in cerebral palsy are permanent and as S.Terver said – ‘The child with cerebral palsy becomes the adult with cerebral palsy’. The main goals of surgical treatment – improving the child’s motor activity and elimination of severe limb deformities.

Method SEMLS, especially when combined with osteotomies, is technically difficult and requires two teams of orthopedic surgeons and anesthesiologist who owns the technique of combined anesthesia.

However, SEMLS changes the whole pathological stereotype of musculoskeletal balance of extremities. It can improve the child’s motor activity, eliminate the severe contractures of joints and provide adequate care for him in a relatively short period of time.

REFERENCES

- Godwin, E.M., Spero, C.R., Nof, L., Rosenthal, R.R., Echternach, J.L.** (2010) 'The gross motor function classification system for cerebral palsy and single-event multilevel surgery: is there a relationship between level of function and intervention over time?' *J Pediatr Orthop.*, 29(8), pp. 910–915.
- Little, W.J.** (1861–62) 'On the influence of abnormal parturition, difficult labours, premature birth, and asphyxia neonatorum, on the mental and physical condition of the child, especially in relation to deformities.' Transcribed from The Obstetric Society of London, 3, p. 293.
- McGinley, J.L., Dobson, F., Ganeshalingam, R., Shore, B.J., Rutz, E., Graham, H.K.** (2012) 'Single-event multilevel surgery for children with cerebral palsy: a systematic review.' *Dev Med Child Neurol.*, 54(2), pp.117–145.
- Moreau, M.J., Lake, D.M.** (1987) 'Outpatient percutaneous heel cord lengthening in children.' *J Pediatr Orthop.*, 7(3), pp.253–255.
- Norlin, R., Tkaczuk, H.** (1985) 'One-session surgery for correction of lower extremity deformities in children with cerebral palsy.' *J Pediatr Orthop.*, 5, pp.208–219.
- O'Shea, T.M.** (2008) 'Diagnosis, treatment, and prevention of cerebral palsy.' *Clin Obstet Gynecol.*, 51(4), pp.816–844.
- Rang, M.** (1990) 'Cerebral palsy.' Lovell and Winter's *Pediatric Orthopaedics*. 3rd edn., pp. 465–506.
- Reimers, J.** (1980) 'The stability of the hip in children a radiological study of results of muscle surgery in cerebral palsy.' *Acta Orthopaedica Scandinavica*, 184, pp.1–100.
- Sychevskij, L.Z., Anosov, V.S., Marmysh, A.G.** (2008) 'Method of Achilles tendon ventralization.' Patent of Belarus N 11213 (in Russian).
- Thomason, P., Selber, P., Graham, H.K.** (2013) 'Single Event Multilevel Surgery in children with bilateral spastic cerebral palsy: a 5 year prospective cohort study.' *Gait Posture*, 37(1), pp.23–31.
- Thomason, P., Pascoe, J., Graham, K., Gough, M.** (2014) 'Single Event Multilevel Surgery (SEMLS) for Children with CP: the evidence from Europe and Australia.' AACPD 68th Annual Meeting.

*Authors reported no source of funding.
Authors declared no conflict of interest.*

*Author responsible for correspondence:
Leanid Hlazkin
Mogilev Regional Children's Hospital
212026, Biruli, 9
Mogilev, Belarus
glazkinl@gmail.com*

*Autorzy nie zgłosili źródła finansowania
Autorzy nie deklarowali konfliktu interesów.*

*Autor odpowiedzialny za korespondencję:
Leanid Hlazkin
Mogilev Regional Children's Hospital
212026, Biruli, 9
Mogilev, Białoruś
glazkinl@gmail.com*