

CASE REPORT

THE BILATERAL ACHILLES TENDON OSSIFICATION SUCCESSFULLY TREATED WITH RECONSTRUCTION USING AUTOLOGOUS SEMITENDINOSUS AND GRACILIS TENDON GRAFT. A A CASE REPORT OF PATIENT WITH CHRONIC RENAL FAILURE

OBUSTRONNE SKOSTNIENIE ŚCIĘGNA ACHILLESA POMYŚLNIE LECZONE REKONSTRUKCJĄ Z UŻYCIEM AUTOLOGICZNEGO PRZESZCZEPU ŚCIĘGIEN MIĘŚNI PÓLBŁONIASTEGO I SMUKŁEGO. OPIS PRZYPADKU PACJENTA Z PRZEWLEKŁĄ NIEWYDOLNOŚCIĄ NEREK

Paweł Bąkowski¹, Jakub Kaszyński¹, Maria Wolff^{1,2}, Kinga Ciemniewska-Gorzela¹, Tomasz Piontek^{1,2}

¹Rehasport Clinic, Orthopedic Department, Poznań, Poland

²Department of Spine Disorders and Pediatric Orthopaedics, University of Medical Sciences, Poznań, Poland

ABSTRACT

Introduction

The issue and problem of Achilles tendon ossification is rarely seen in scientific literature, and there is no consensus in the treatment.

Aim

The aim of this study is to present a case of heterotopic ossification with a bilateral location within the Achilles tendon together with its method of surgical treatment.

Material and methods

A 28-year-old woman had presented heterotopic ossification located within the Achilles tendon. Ossification had occurred after a prolonged use of steroids resulting in severe pain, dysfunction and chronic oedema. In the presented case we had performed bilateral Achilles tendon reconstruction using semitendinosus and gracilis tendon with Endobutton stabilization. A 2-year follow up of the presented patient has proven this method successful.

Conclusion

Our novel procedure may be a good option of treatment for patients with large ossifications or large Achilles tendon defects. It's main principles are reconstruction of the Achilles tendon's continuity and function as well as the use of autologous tendons of the semitendiosus and gracilis muscles, what does not weaken the foot.

Keywords: Achilles tendon, ossification, reconstruction, case report

Author responsible for correspondence:

Paweł Bąkowski, Rehasport Clinic, Górecka Str. 30, 60-201 Poznań, Poland
e-mail: pawel.bakowski@rehasport.pl

Date received: 22nd February 2019

Date accepted: 28th February 2019

Authors reported no source of funding

Authors declared no conflict of interest

STRESZCZENIE

Wstęp

Przypadki skostnień ścięgna Achillesa i problemy z nimi związane są rzadko spotykane i opisywane w piśmiennictwie. Również z tego powodu nie ma wypracowanego konsensusu w leczeniu tego typu przypadków.

Cel

Celem tej pracy jest przedstawienie przypadku skostnień pozaszkieletowych obu ścięgien Achillesa oraz ich leczenia operacyjnego.

Materiał i metody

Skostnienia pozaszkieletowe wystąpiły w obu ścięgnach Achillesa u 28-letniej kobiety w przebiegu długotrwałej sterydoterapii. Skostnienia spowodowały powstanie dolegliwości bólowych, dysfunkcji oraz przewlekłych obrzęków. W opisanym przypadku wykonano obustronnie rekonstrukcję ścięgna Achillesa, wykorzystując ścięgna mięśnia półścięgnistego i smukłego ze stabilizacją blaszką Endo-button. Okres 2-letniej obserwacji dowiódł skuteczności tej metody leczenia.

Wnioski

Opisana nowatorska metoda leczenia może być dobrą opcją leczenia pacjentów z dużymi skostnieniami pozaszkieletowymi ścięgna Achillesa. Jej głównymi elementami są odtworzenie ciągłości i funkcji ścięgna Achillesa oraz zastosowanie autologicznych ścięgien mięśni półścięgnistego i smukłego, co nie osłabia mięśni stopy.

Słowa kluczowe: ścięgno Achillesa, skostnienia, rekonstrukcja, opis przypadku

Introduction

Ossification of the Achilles tendon is a rare clinical condition associated with the presence of variously sized and quantities of ossified mass within the structure of the tendon (Richards *et al.*, 2008; Yu *et al.*, 1994; Tamam *et al.*, 2011; Ghormley, 1938) This article presents a case of heterotopic ossification with bilateral location within the Achilles tendon of a 28-year old female patient having undergone treatment in our clinic in 2011–2013. We had performed a novel reconstruction technique of the Achilles tendon, using autologous hamstring grafts.

Aim

The aim of this study is to present a case of heterotopic ossification with a bilateral location within the Achilles tendon together with its method of surgical treatment.

Case presentation

In 1991 the patient had been diagnosed with chronic glomerulonephritis. Since then, the deterioration of kidney function had been observed. For this reason, the patient had undergone dialysis from August to December 1996, followed by left kidney transplantation from a living-related donor. Due to relapse, the primary graft had been removed in 1999. Afterwards, the patient had once again undergone dialysis, then hemodialysis and after 6 months peritoneal dialysis had been introduced. Another kidney transplant had been performed in 2003 from an unrelated donor. The organ has been functioning properly till today. Current medication includes azathioprine 100 mg (50 mg 2 × 1), 5 mg prednisone, tacrolimus 2 mg (1 mg 2 × 1).

The patient also suffers from developmental left hip dysplasia. In her childhood she had been treated conservatively. Due to secondary degenerative changes appearing in 2010, a cementless total left hip arthroplasty (Aesculap) had been performed. Currently the patient presents no symptoms from the operated hip joint.

In 2011 the patient had complained of severe right Achilles pain. At that time gait pattern disturbance (limping on the right lower limb, shortening the phase of reflection) had been

observed. On palpation, the patient had presented clearly distinguishable pain in the Achilles tendon, slight swelling and slight limitation in the range of motion in the ankle. On the left side the patient's symptoms had proven similar, although with far less severity. There was no medical history of trauma, previous surgery of the Achilles tendon or musculoskeletal nor any systemic disorders in the patient's personal or family medical record.

The suspected clinical diagnosis of bilateral Achilles tendon ossification had been confirmed by plain radiography and an ultrasound examination (Fig.1). The ultrasound examination had presented deposits clustered in irregular conglomerates, in some places covering the entire cross-section of the tendon. The decision to perform surgical treatment had been made in consideration of the patient's age, symptoms, co-morbidities and activity level, as well as the patient's wish to proceed with the suggested treatment plan.

Surgical treatment

Right lower limb

The operation had been performed with spinal anesthesia. The patient had been placed stomach down. Skin incision, the length of 12 cm, had been performed medially next to the midline, in order to avoid damage to the sural nerve, and also to protect the delicate skin lying directly on the outer surface of the tendon. After finding the ossifications, the tendon had been prepared by its removing (Fig.2). The gap between the proximal and distal stump of the patient had exceeded 6 cm from the ankle in maximal plantar flexion. Due to this fact the decision to perform Achilles tendon reconstruction had been made.

We had used semitendinosus and gracilis tendons (ST and GR) from the damaged lower limb and prepared them for the Endobutton device (Smith and Nephew, Andover, MA, USA) giving a graft 9mm in diameter and 12 cm in length. Then, the calcaneus had been drilled through using K-wire. The next step of the procedure was drilling by use of a 4.5 mm drill, the measurement of the tunnel length, and its extension to the adequate size (depending on

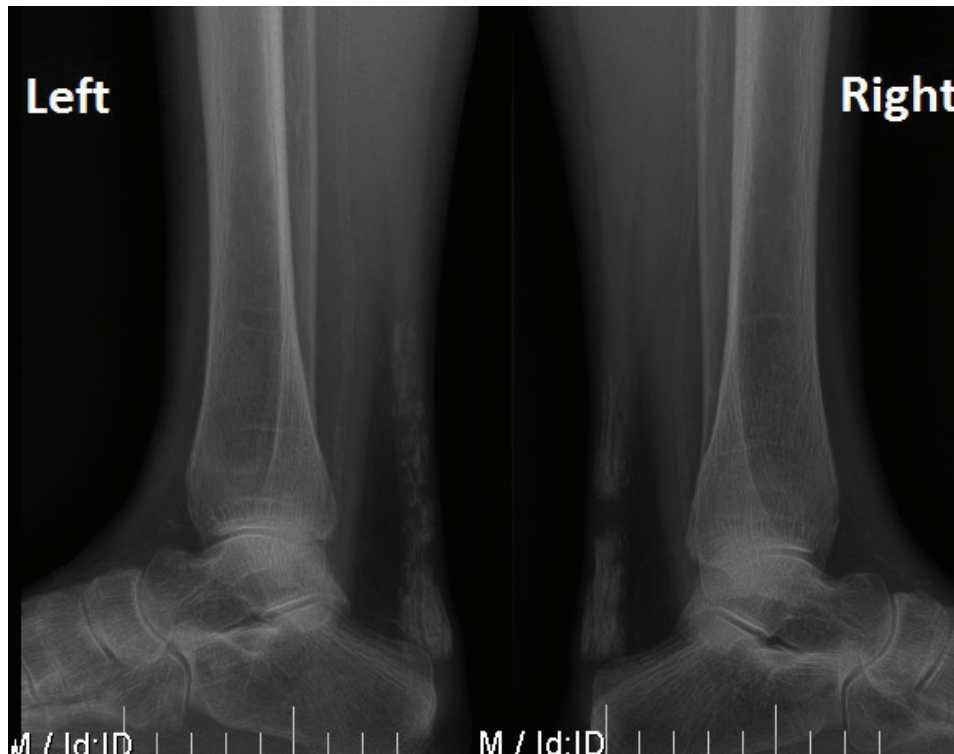


Figure 1. X-rays taken preoperatively showing massive ossification in both Achilles tendons.

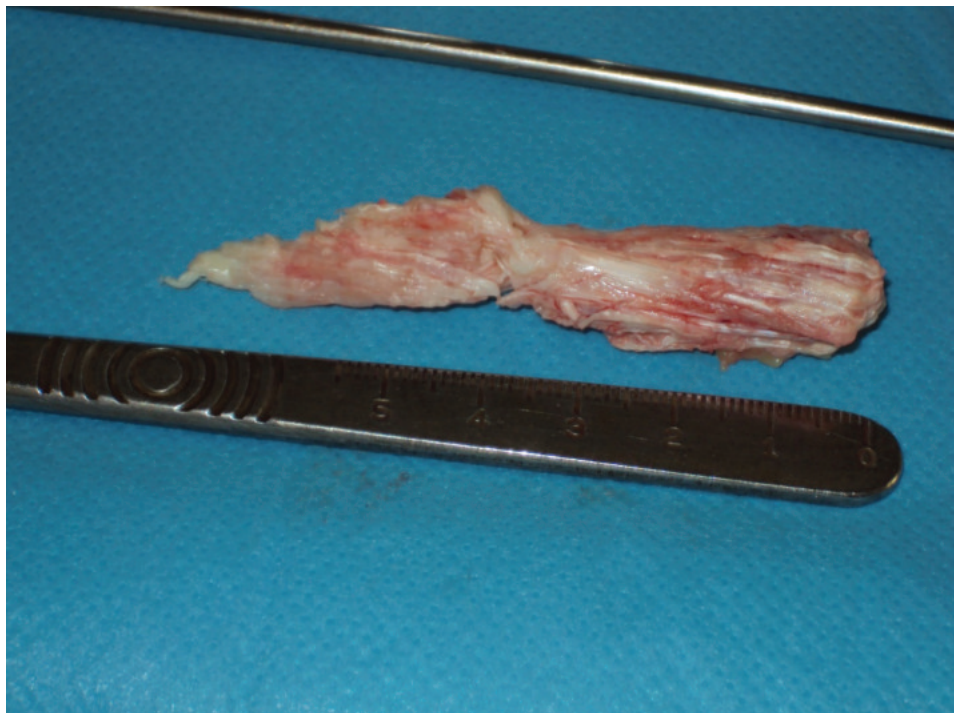
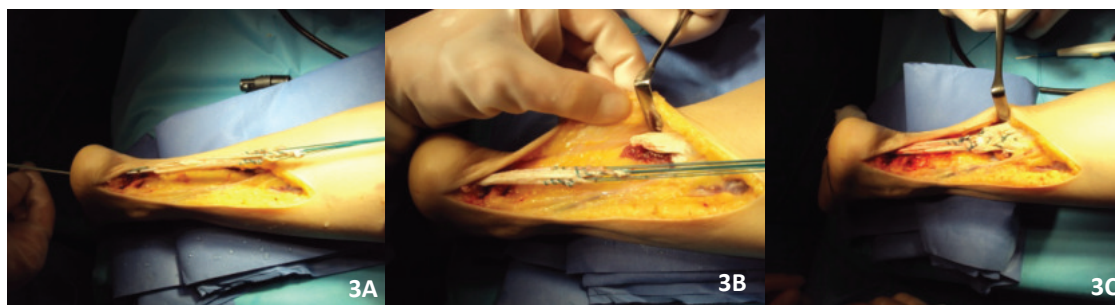


Figure 2. Removed tendon with ossifications.

graft size), maintaining the distal cortex of the heel in reliance to the corresponding Endo-button fixation. The distal end of the graft equipped with an Endo-button loop had been entered into the drilled tunnel in the calcaneus. The proximal end of the graft had been sutured with the stump of the Achilles tendon by use of nonabsorbable 2 Ethibond suture (Fig. 3A–3C). After hemostatic control the subcutaneous tissue had been closed using 4–0 absorbable suture and the skin had been closed using adaptive 3–0 sutures.

presents recurrence of symptoms from the plantar fascia on the left side (despite good results in the follow-up 6 months post-surgery).

The physical examination of the Achilles tendon of the lower left limb proves to be thinner than the right side. Noticeable thickening of the plantar fascia in the lower left limb. Surgical scars had healed properly. The Thompson test had proven correct plantar flexion in both legs. The patient is able to tip-toe.



Figures 3A–3C. Achilles tendon reconstruction using semitendinosus and gracilis tendons with Endobutton stabilization.

Due to the escalating problems in the left leg, in June 2012, a similar procedure had been performed.

Post-operative history

The follow up ultrasound in January 2013 had revealed swelling of the tissue in the area of transplant mounting, a large amount of mineralization within the plantar fascia, and single ossification within the left Achilles tendon. In February 2013, on an outpatient basis, 4 radiation fractions (1Gy dose each) in the area of the left Achilles tendon had been administered. Due to pain caused by ossification around the left foot, a surgical procedure had been performed in April 2014, based on endoscopic cleansing of the left plantar fascia heel attachment and Endobutton plaque removal. Due to the soft tissue scar and fibrosis after hematoma, another endoscopic procedure had been performed in June 2014.

Results

The patient had been assessed in April 2015

The patient walks independently, without limping. While walking, she does not report any pain in the Achilles tendon areas. Currently the patient

The patient is satisfied with the results of the reconstruction of both Achilles tendons. On the question of undergoing this procedure once again, the patient had answered affirmatively.

We had also determined the VAS pain scale, the VAS satisfaction scale, the AOFAS scale, ATRS scale and the quality of life of WHO (WHOQOL-BREF), whose results have been presented in the table.

The functional assessment

Evaluation with Functional Movement Screen, Riva test using the DELOS system, Star Excursion Balance Test and the Weight-Bearing Lunge Test has been used. Level of postural control measured with the Riva test showed that, while standing on the left leg patient used an inadequate strategy in dynamic conditions. Furthermore patient used an impaired visual-proprioceptive strategy to keep the balance on the right leg. The remaining tests had shown good control in movement patterns involving lateral stabilizers of the ankle joint, however they confirmed reduced range of ankle dorsiflexion.

Table 1. Surgical procedures performed in our clinic.

Date	Operated limb	Surgical procedure
28.11.2011	Right leg	The reconstruction of the Achilles tendon with autologous hamstrings grafts
21.06.2012	Left leg	Removal of ossification; the Achilles tendon augmentation with autologous hamstring grafts
14.04.2014	Left leg	Endoscopic cleansing of the plantar fascia heel attachment and Endobutton plaque removal
2.06.2014	Left leg	Revision endoscopic cleansing of the plantar fascia heel attachment

Table 2. Results in 2-year follow up scores.

Scale	Result	Max
VAS pain	2	10
VAS satisfaction	10	10
AOFAS	90	100
ATRS	84	100

Table 3. Test used on our functional assessment and its basis.

Test	Basis
FMS	The assessment of the basic movement patterns according to the protocol evaluation. Based on the analysis of the performed movement patterns announces the functional range of motion in the joints of the lower limbs and upper limbs, muscular trunk and limbs stability and the neuro - muscular control and postural strategies.
Riva test	Using the appropriate system devices based on the assessment of the dynamic and static balance test, determines irregularities in the visual and vestibular systems.
SEBT	Star Excursion Balance Test allows to evaluate the functional dynamic stability of a person.

Radiographic assessment

X-rays were performed in the lateral standing position for both legs (Figures 4A for the left lower limb, Figure 5A for the right lower limb). Additionally MRI scans were performed (Figure 4B and 4C for left lower limb, Figure 5B and 5C for right lower limb) to confirm Achilles tendons restored continuity. Normal cross-sectional area, texture and no evidence of degeneration and lack of ossifications were proven.

Discussion

The most important finding of this case report is the fact, that presented case of a 28-year old woman proves the convenience of our method. In the presented case, bilateral Achilles tendon reconstruction, using autologous hamstring grafts had been performed. The Achilles tendon reconstruction technique, by use of autologous hamstring graft, provides good functional outcomes.

The issue and problem of Achilles tendon ossification is rarely seen in scientific literature. Literature reviews prove ossification formation to be unclear. More than half the cases involve early trauma or injuries, and surgical procedures within the Achilles tendon. Researchers also present other common etiologies, such as fluorosis, diabetes, kidney failure, Wilson's disease, gout, ochronosis, diffuse idiopathic skeletal hyperostosis, seronegative hyperostosis, use of certain drugs (Richards *et al.*, 2008; Yu *et al.*, 1994; Tamam *et al.*, 2011; Wuenschel *et al.*, 2010).

Already in 1970, Fisher had reported that ossification most likely results from degenerative changes in fibers, which can be caused by vascular insufficiency (Fischer *et al.* (1970)). In the presented case, both bilateral rise of ossification within the Achilles tendon, as well as within the plantar fascia, had probably appeared due to

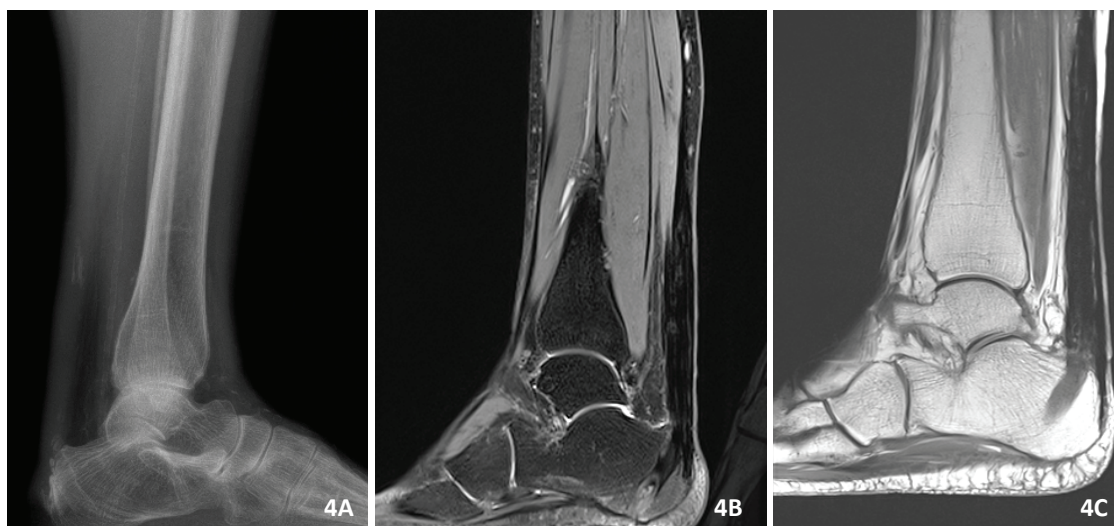


Figure 4A. 3-year postoperatively X-ray image of the left Achilles tendon; 4B and 4C - MRI scans of the reconstructed left Achilles tendon.

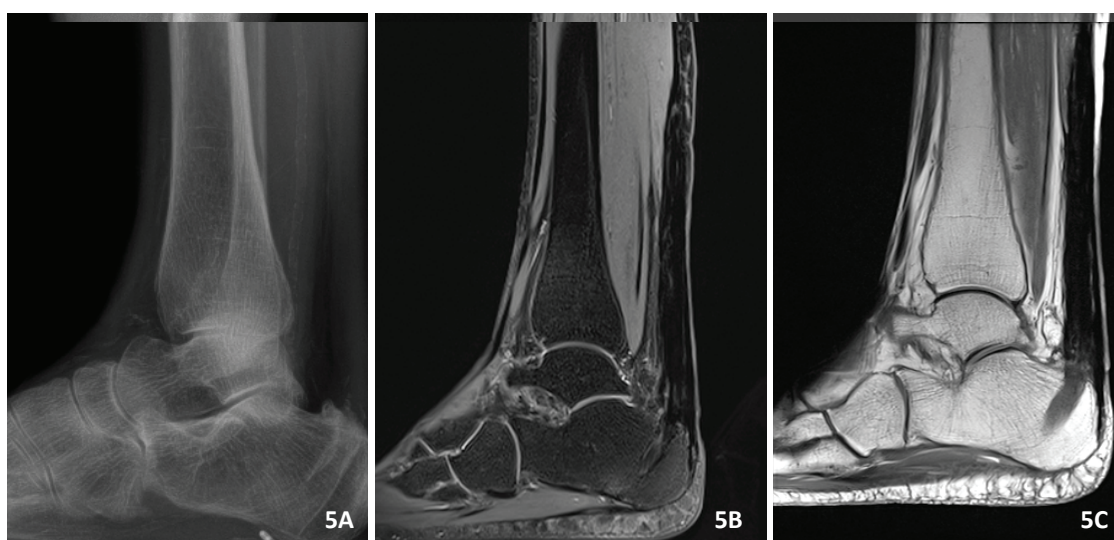


Figure 5A. 3-year postoperatively X-ray image of the right Achilles tendon; 5B and 5C - MRI scans of the reconstructed right Achilles tendon.

the chronic renal failure disease and also due to long-term use of immunosuppressive drugs.

Typically, this kind of ossification does not cause significant symptoms and does not reduce the quality of life, yet may lead to the development of inflammation, causing acute pain and limitation in the range of motion (Richards *et al.*, 2008; Yu *et al.*, 1994; Lothke *et al.*, 1970). Due to the patient having presented complications such as pain, reduced range of motion, substantial disturbances of gait pattern and the absence of a positive effect of non-surgical treatment, it had been decided to reconstruct the Achilles tendons. Reconstruction was performed by use of

autologous hamstring grafts, which technique is successfully used in our clinic for the last 5 years. The main indication for the use of this method was neglected Achilles ruptures with end gap more than 6 cm and neglected partial damage (including over 50% of tendon fibers) with dysfunctional Achilles tendon (Piontek *et al.*, 2015).

Conclusions

Achilles tendon reconstruction with autologous semitendinous and gracilis graft may be a good option of treatment for patients with large ossifications or large Achilles tendon defects. The restoration of tendons continuity and function,

preservation of foot's strength and fast rehabilitation protocol seems to be crucial in treating the most difficult cases of chronic Achilles tendon tears.

REFERENCES

- Fisher T.R., Woods C.G.** (1970) *Partial rupture of the tendo calcaneus with heterotropic ossification. Report of a case.* J Bone Joint Surg. Br., 52: pp. 334–336.
- Ghormley J.W.** (1938) *Ossification of the tendon Achilles.* J Bone Joint Surg, 20; pp. 153–156.
- Lothke P.A.** (1970) *Ossification of the Achilles tendon.* J Bone Joint Surg Am., 52: pp. 157–160.
- Piontek T., Bańkowski P., Ciemnińska-Gorzela K., Naczek J.** (2015) *Novel Technique of Achilles Tendon Reconstruction Using Semitendinosus and Gracilis Tendon. Preliminary Report.* OrtopTraumatolRehabil., 17(6): pp. 619–625.
- Richards P.J., Braid J.C., Carmont M.R., Maffulli N.** (2008) *Achilles tendon ossification: pathology, imaging and aetiology.* Disabil Rehabil., 30: pp. 1651–1665.
- Sobel E., Giorgini R., Hilfer J., Rostkowski T.** (2002) *Ossification of a ruptured achilles tendon: a case report in a diabetic patient.* J Foot Ankle Surg., 41: pp. 330–334.
- Tamam C., Yildirim D., Tamam M., Mulazimoglu M., Ozpacaci T.** (2011) *Bilateral Achilles tendon ossification: diagnosis with ultrasonography and Single Photon Emission Computed Tomography/Computed Tomography. Case report.* Med Ultrason., 13(4); pp. 320–322.
- Wuenschel M., Trobisch P.** (2010) *Achilles tendon ossification after treatment with acitretin.* J Dermatolog Treat., 21: pp. 111–113.
- Yu J.S., Witte D., Resnick D., Pogue W.** (1994) *Ossification of the Achilles tendon: imaging abnormalities in 12 patients.* Skeletal Radiol., 23: pp. 127–131.