

SHORT COMMUNICATION

RETROSPECTIVE ANALYSIS OF PATIENTS WITH SIMPLE BONE CYST

ANALIZA RETROSPEKTYWNA PACJENTÓW Z TORBIELĄ SAMOTNĄ KOŚCI

Maciej Kasprzyk, Michał Łuczak, Anna Wawrzyniak, Leszek Romanowski

Department of Traumatology, Orthopaedics and Hand Surgery, Poznan University of Medical Science, Poznań, Poland

ABSTRACT

Introduction

Simple bone cyst is benign fluid-filled lesion localized mainly in long bones. It is usually diagnosed in the first two decades, the most common in proximal humerus. Unicameral bone cyst is often asymptomatic but can cause pathological fracture.

Aim of the study

The aim of our study was to evaluate clinical, diagnostic and treatment factors concerning patients with simple bone cyst.

Material and methods

The retrospective analysis was performed on 22 patients treated in Department of Traumatology, Orthopaedics and Hand Surgery in Poznań between 2001 and 2017. We have analyzed epidemiological factors: age and sex; symptoms; clinical examination: range of motion, presence of pain; X-ray: localisation, cyst index of Kaelin and MacEwan and presence of pathological fractures; treatment: methods, number of hospitalizations and effectiveness.

Results


Mean age of patients was 10.8. From 22 patients 11 were females. Generally bone cyst was diagnosed because of pathological fracture – 18 patients (85.7%). Other reasons of X-ray diagnostic were: pain – 2 patients (9.1%), deformity – 1 patient (4.5%), incidentally – 2 patients (9.1%). The bone cyst was localized in humerus – 21 patients (95.5%), radius – 1 patient (4.5%). Treatment methods were various: 7 patients (31.8%) – Depomedrol injections, 4 patients (18.1%) – marrow injections, 4 patients (18.1%) – marrow and Depomedrol injections, 5 patients (22.7%) – injections with additional bone grafts, 3 patients (13.6%) – only bone grafts.

Conclusions

Simple bone cyst occurs generally in young people (under twenty). The most common problem is a pathological fracture. Treatment is long and multistage.

Keywords: SBC, simple bone cyst, retrospective analysis

Author responsible for correspondence:

Maciej Kasprzyk
Department of Traumatology, Orthopaedics and Hand Surgery
Poznan University of Medical Science
28 Czerwca 1956 Str No 135/147
61-545 Poznań
e-mail: kasprzykm1993@o2.pl, +48723481998
 <https://orcid.org/0000-0002-2083-0920>

Authors reported no source of funding
Authors declared no conflict of interest

Date received: 21th August 2020
Date accepted: 5th October 2020

STRESZCZENIE

Wstęp

Torbiel samotna kości jest łagodną zmianą wypełnioną płynem, zlokalizowaną głównie w kościach długich. Zwykle rozpoznaje się ją w pierwszych dwóch dekadach, najczęściej w części proksymalnej kości ramiennej. Torbiel samotna kości często przebiega bezobjawowo, ale może powodować patologiczne złamanie.

Cel pracy

Celem pracy była ocena klinicznych, diagnostycznych i terapeutycznych czynników dotyczących pacjentów z torbielą samotną kości.

Materiał i metody

Retrospektywną analizę przeprowadzono na 22 pacjentach leczonych w Klinice Traumatologii, Ortopedii i Chirurgii Ręki w Poznaniu w latach 2001–2017. Przeanalizowaliśmy czynniki epidemiologiczne: wiek i płeć; objawy; badanie kliniczne: zakres ruchu, obecność bólu; w badaniu RTG: lokalizację, wskaźnik Kaelina i MacEwana oraz obecność patologicznych złamań, a także metody leczenia, liczbę hospitalizacji i skuteczność leczenia.

Wyniki

Średni wiek pacjentów wynosił 10,8 lat. Spośród 22 pacjentów 11 było kobietami. Torbiel samotną kości rozpoznawano głównie z powodu patologicznego złamania – 18 pacjentów (85,7%). Innymi przyczynami diagnostyki RTG były: ból – 2 osoby (9,1%), deformacja – 1 pacjent (4,5%), incydentalnie – 2 osoby (9,1%). Torbiel samotną kości lokalizowała się w kości ramiennej u 21 pacjentów (95,5%), promieniowej u 1 pacjenta (4,5%). Metody leczenia były różne: 7 pacjentów (31,8%) – zastrzyki depomedrolu, 4 pacjentów (18,1%) – podanie szpiku kostnego, 4 pacjentów (18,1%) – podanie szpiku i depomedrolu, 5 pacjentów (22,7%) – iniekcje z dodatkowymi przeszczepami kostnymi, 3 pacjentów (13,6%) – same przeszczepy kostne.

Wniosek

Torbiel samotna kości występuje na ogół u młodych ludzi (poniżej dwudziestego roku życia). Najczęstszym problemem jest złamanie patologiczne. Leczenie jest długie i wieloetapowe.

Słowa kluczowe: SBC, torbiel samotna kości, analiza retrospektywna

Introduction

The simple bone cyst (SBC) otherwise called unicameral bone cyst is the most common benign tumour in juveniles. It almost always occurs in the metaphysis of long bones, especially in proximal humerus and proximal femur. It is often asymptomatic but can cause pathological fracture, deformity or pain. SBC generally occurs in children, adolescents and young adults under 20 years old with no difference in occurrence between boys and girls (Biermann, 2002; Yildiz *et al.*, 2003; Uli and Em, 2015).

Diagnosis is usually made by characteristic image on X-ray such as: osteolysis (which results in high radiolucency), no periosteal reaction (except pathological fractures), clear border between cyst and surrounding bone, no destruction of the growth cartilage, location within diaphysis or the metaphysis of a long bone. It is important to distinguish SBC from osteomyelitis, aneurysmal bone cyst, fibrous dysplasia, giant cell tumor due to similar radiological view (Wyers, 2010).

There is no clear consensus about the best treatment option for SBC (Zhao *et al.*, 2013). It is believed that SBC in some cases may resolve while obtaining skeletal maturity. In some cases observation may be considered as one of the treatment options but there are often indications for surgical treatment: steroid injection, autologous bone marrow injection, autograft, allograft or bone substitute. Sometimes decompression is needed including multiple drilling with or without cannulated screw insertion or elastic intramedullary nailing (Santori, Ghera and Castelli, 1988; Saraph *et al.*, 2004; Zhao *et al.*, 2013).

The purpose of our study was to perform the retrospective analysis of patients with simple bone cyst treated in our department by evaluation of demographic and clinical factors, localization of the cyst, radiographic findings and treatment methods. Especially we had concerned on number of hospitalizations needed to treat the patient and number of application of each treatment method.

Materials and methods

From 2001 to 2017, 22 patients were admitted to the Department of Traumatology, Orthopaedics and Hand Surgery in Poznań University of Medical Sciences due to SBC. Diagnosis was confirmed as the result of clinical examination and characteristic appearance on X-ray. The median age at the beginning of treatment was 10 (range 3–61), 86% of patients were under 20 years old. In our study 11 males and 11 females were

included. The cyst localization was humerus in 21 cases and radial bone in 1 case.

Generally bone cyst was diagnosed because of pathological fracture – 15 patients (68.2%). Other reasons of X-ray diagnostic were: pain – 4 patients (18.2%), deformity – 1 patient (4.5%), incidentally – 2 patients (9.1%).

We performed the measurement of the SBC by using the WEASIS software. We had measured the area on the anterior-posterior radiograph and calculated cyst index of the Kaelin and MacEwen (CI) (Kaelin and MacEwen, 1989). CI may be calculated by dividing area of a SBC on plain radiograph by squared diaphysis diameter.

Unfortunately only 11 patients had digital X-ray available.

In our department SBC was treated by using: percutaneous steroid injection (Depomedrol), autogenous bone marrow injection (ABMI), autograft, allograft and bone substitutes.

We have performed the statistical analysis by using STATISTICA 13 software.

Results

We have analyzed the application of different treatment methods, number of hospitalizations and measurements of bone cyst index. One treatment method was applied in 13 cases, two in 7 cases and three in 2 cases (Figure 1).

Steroid injection was averagely applied 3.6 times, ABMI 2.5 times. Autograft, allograft and bone substitute was used averagely one time (Figure 2).

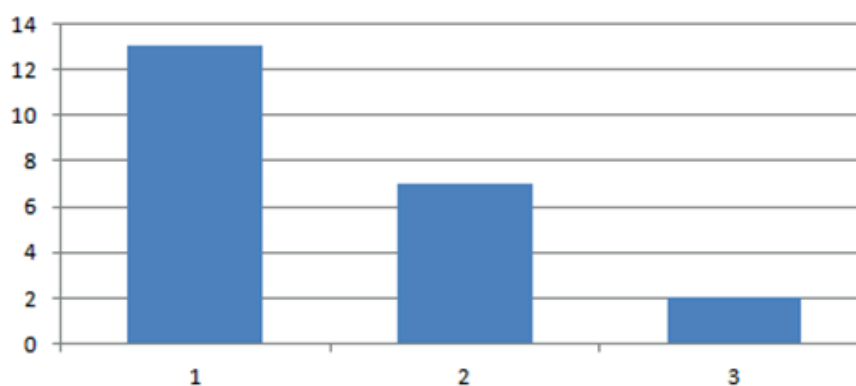


Figure 1. Number of different treatment methods applied.

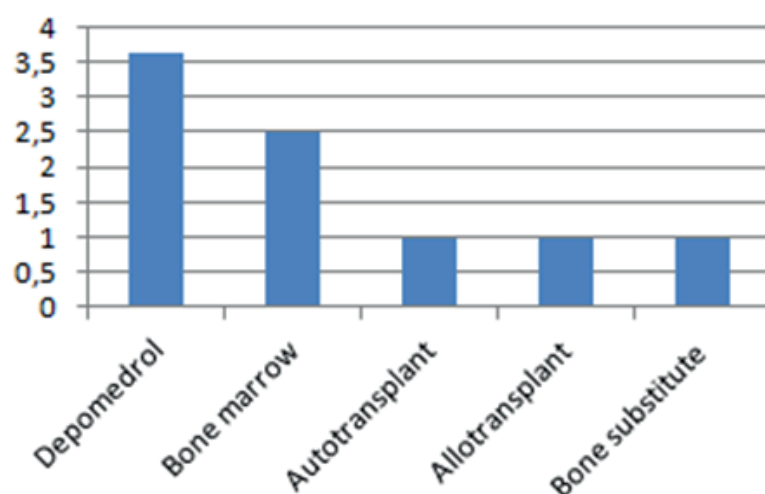


Figure 2. Summary of treatment methods.

Treatment methods were various as it follows: 7 patients (30.4%) – only percutaneous steroid injections, 4 patients (17.4%) – only ABMI, 4 patients (17.4%) – ABMI and percutaneous injections, 5 patients (21.7%) – injections with additional grafts, 3 patients (13%) – only grafts (autograft, allograft and bone substitute) (Figure 3).

Discussion

As SBC is not a real neoplasm and the main goal of the treatment is to reduce a risk of pathological fracture it is critical to assess a probability of such incident. To do this we have decided to use cyst index of Kaelin and Mc Ewan as it is proved that it is correlated with risk of a pathological fracture (Kaelin and Macewen, 1989).

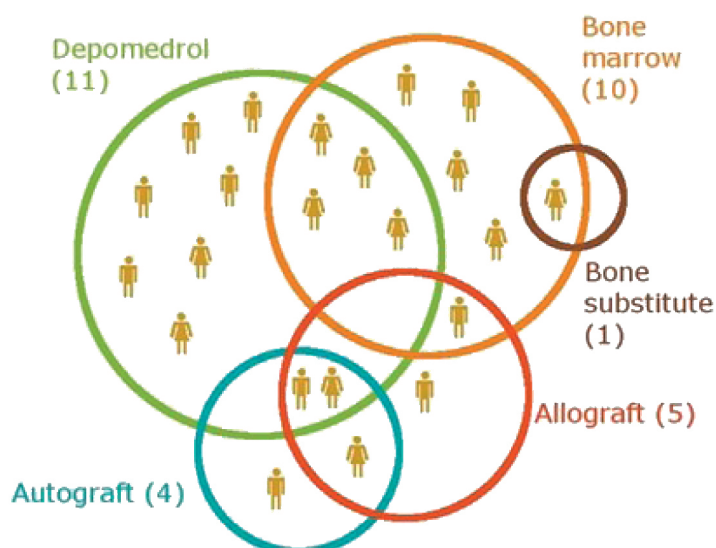


Figure 3. Applied treatment methods in a group of patients.

Mean number of hospitalization was 4.2 times and our analysis showed that patients treated with Depomedrol were hospitalized more times than those that were not ($p < 0.05$).

As CI was proposed when personal computers have not been widely available (1989) area of a cyst was estimated by drawing trapezoids around borders of a SBC. We have decided to use computer software (Weasis) to calculate this

area as it is more accurate method. In a group of patients that have available radiographs (11 out of 22) we have measured correlation between CI and number of fractures. We haven't achieved statistically significant correlation; it may be result of too small study group.

In our and Bierman (2002) observation the occurrence of SBC in males and females are equal but other researches show the predominance of males (Kaelin and MacEwen, 1989). The SBC are mainly located in humerus in all available papers.

There are no consensus what is the best treatment option, some authors are in favor of bone marrow injection (Santori, Ghera and Castelli, 1988; Saraph *et al.*, 2004; Cho *et al.*, 2007), although bone marrow injection are more invasive. The main advantage of ABMI is that it require fewer hospitalizations than steroid injection what we also proved in our research. On the other hand Zhao JG *et al.* in Cochrane review has stated that available evidences are insufficient to determine the relative effects of bone marrow versus steroid injections. What is more fewer patients after bone marrow injection had treatment success based on assessment on X-ray (Zhao *et al.*, 2013). Uli A *et al.* (2015) recommend more radical surgical procedures such as diaphysectomy and elastic reinforcement only in case of conservative management failure and in cases of displaced pathological fractures (Saraph *et al.*, 2004).

There is a necessity for more good quality RCTs on intervention in the treatment of simple bone cyst with taking into account of anatomic localization and cost-effectiveness of each method. Number of hospitalization needed to treat may have impact on selection method of treatment if we cannot prove superiority of treatment methods. We still know little about natural history of SBC.

Conclusions

Patients that were treated with Depomedrol were hospitalized more times than those who were not treated with Depomedrol ($p < 0.05$).

Until now there is no consensus what treatment method should be applied to patients

with simple bone cyst, but for sure the main goal of the treatment should be to decrease the risk of a pathological fracture and as in some patients this risk is very small we should also consider observation as one of the treatment options. Cyst index is still good method of assessing risk of fracture.

REFERENCES

- Biermann, J. S.** (2002) 'Common benign lesions of bone in children and adolescents', *Journal of Pediatric Orthopaedics*, 22(2), pp. 268–273.
- Cho, H. S. Oh, J. H. Kim, H-S. Kang H. G. Lee, S. H.** (2007) 'Unicameral bone cysts: a comparison of injection of steroid and grafting with autologous bone marrow', *Journal of Bone and Joint Surgery – British Volume*, 89-B(2), pp. 222–226.
- Kaelin, A. J. and MacEwen, G. D.** (1989) 'Unicameral bone cysts – Natural history and the risk of fracture', *International Orthopaedics*, 13(4), pp. 275–282.
- Santori, E., Ghera, S. and Castelli, V.** (1988) 'Treatment of solitary bone cysts with intramedullary nailing', *Orthopedics*, 11(6), pp. 873–878.
- Saraph, V. Zwick, E-B. Maizen, C. Schneider, F. Linhart, W.** (2004) 'Treatment of Unicameral Calcaneal Bone Cysts in Children', *Journal of Pediatric Orthopaedics*, 24(5), pp. 568–573.
- Uli, A. and Em, C.** (2015) 'The modern treatment of the simple bone cysts', *Journal of Medicine and Life*, 5(1), pp. 469–473.
- Wyers, M. R.** (2010) 'Evaluation of pediatric bone lesions', *Pediatric Radiology*, pp. 468–473. doi: 10.1007/s00247-010-1547-4.
- Yildiz, C. Erler, K. Atesalp A. S. Basbozkurt, M.** (2003) 'Benign bone tumors in children', *Current Opinion in Pediatrics*, 15(1), pp. 58–67.
- Zhao, J. G. Wang, J. Huang, W. J. Zhang, P. Ding, N. Shang, J.** (2013) 'Interventions for treating simple bone cysts in the long bones of children', *Cochrane Database of Systematic Reviews*, 2013(11).