Short communication DOI: 10.19271/IRONS-000152-2021-37

Proste zwichnięcia stawu łokciowego – od diagnozy do leczenia

STRESZCZENIE

Wprowadzenie

Zwichnięcie łokcia jest powszechnym urazem, który można spotkać na izbie przyjęć. Każde zwichnięcie może być zakwalifikowane jako proste lub złożone w zależności od obecności urazów kostnych, a ich leczenie zależy głównie od rodzaju uszkodzenia jak też od stabilności stawu po zamkniętym nastawieniu.

Cel

Celem tego przeglądu jest zaprezentowanie aktualnej wiedzy dotyczącej diagnostyki i leczenia prostych zwichnięć stawu łokciowego oraz by zaproponować algorytm, na bazie którego można by prawidłowo zaopatrzyć pacjenta.

Materiał i Metody

Dwanaście artykułów od 1999-2020 roku korzystając z zasobów PubMed, Biblioteki Cochrane zostało zanalizowanych w poszukiwaniu opartych na faktach metod postępowania, które wiążą się z najlepszym wynikiem leczenia po ostrym zwichnięciu stawu łokciowego.

Wyniki

Szybka mobilizacja w stabilnym zakresie ruchomości po nastawieniu stawu znacząco redukuje ryzyko późnych powikłań oraz bólu. Dokładne badanie uszkodzonego stawu jest kluczowe w kontekście wyboru metody leczenia. W mniejszości przypadków z utrzymującą się niestabilnością leczenie operacyjne jest leczeniem z wyboru.

Wnioski

W większości przypadków prostego zwichnięcia łokcia, prawidłowe postępowanie zachowawcze przynosi dobre efekty a sztywność łokcia i ograniczenie zakresu ruchomości są rzadkie. W niektórych sytuacjach jednak leczenie operacyjne jest konieczne.

Słowa kluczowe: ostre zwichnięcie łokcia, epidemiologia, diagnostyka, leczenie

Simple Elbow Dislocations - from Diagnosis to Treatment

Adrian Błasiak 0000-0002-9368-9980, Mikołaj Władyslaw Podsiadło, Wojciech Solecki, Hubert Laprus, Roman Brzóska

Shoulder and Upper Limb Department, St. Luke's Hospital, Bielsko-Biała, Poland

SUMMARY

Introduction

Elbow dislocation is a common injury that one may encounter in an emergency setting. Every dislocation can be categorized as simple or complex depending on bony involvement and treatment depends mainly on injury pattern as well as on post-reduction stability.

Aim

The aim of this review is to present current state of art concerning diagnosis and treatment of simple elbow dislocations and to propose an algorithm, based on which one might successfully provide patient with adequate care.

Material and Methods

Twelve papers dating back from 1999 to 2020 using PubMed, Cochrane Library were reviewed in search of evidence based treatment methods associated with best results after acute elbow dislocation.

Results
Quick mobilization in a stable range of motion after joint reduction reduces greatly the risk of long term complications and pain. Careful examination of the joint involved is crucial in terms of correct therapy selection. In minority of cases with persisting instability operative treatment is the treatment of choice.
Conclusions
In most cases involving simple elbow dislocations, appropriate conservative treatment brings favorable results and elbow stiffness or range of motion (ROM) restriction are rare. However in rare cases the operative repair is mandatory.

Keywords: acute elbow dislocation, epidemiology, diagnosis, treatment

Date received: 26th August 2021 *Date accepted: 18th September 2021*
Authors reported no source of funding.
Authors declared no conflict of interest.

Author responsible for correspondence:
Adrian Błasiak
Shoulder and Upper Limb Department
St. Luke's Hospital
Bystrzanska 94B
43-309 Bielsko-Biała
Poland
email: adrblasiak@gmail.com

INTRODUCTION

The elbow joint is considered to be the second after shoulder most often dislocated joint (Robinson et al. 2017). The injury pattern is each time slightly different but generally one may divide all elbow dislocations into 2 groups. Simple encompassing cases without bony involvement and complex with displaced fractures above 2 mm of bony avulsion in diameter. Simple dislocations are predominantly treated non-operatively first in a sling and a hinged brace afterwards with gradually increasing range of motion and the long term results are satisfactory in around 92 % of cases. Nevertheless there is a small group of patients suffering from a simple elbow dislocation who if treated non-operatively are at risk of developing chronic joint pain, stiffness and instability. (Robinson et al., 2017)
.

Epidemiology

The annual incidence rate is around 5.2-13/100.000 per year (Calderazzi et al., 2020; Rezaie et al., 2020) with slight male predominance most frequently below 30 years of age. The most common injury mechanism is often referred by the patients as a fall from height directly on an outstretched or slightly flexed hand or during direct assault or contact sports. Simple elbow dislocations can be grouped into posterolateral, posterior, posteromedial, divergent (pediatric injuries), and anterior dislocations (rare without fractures). The most common direction of elbow joint dislocation is posterolateral (Singh et al., 2020)

Anatomy

The elbow is stabilized anatomically both statically and dynamically, moreover it is possible to further differentiate between primary static and secondary static stabilizers that resemble outer and inner wall of a castle. The structures responsible for dynamic constraint are muscles that cross the elbow joint such as biceps, triceps and brachioradialis with anconeus. Flexor and extensor common tendons along with radiohumeral joint complete the ulnar integrity becoming thus altogether secondary stabilizers (Figures 1 and 2). Nevertheless primarily the joint is kept stable with the help of congruent ulnohumeral articulation, anterior bundle of the medial collateral ligament and in addition lateral ulnar collateral ligament. According to (Armstrong, 2015) if these three primary elbow structures are intact, then for the most part the elbow is stable (Figure 3).

Figure 1. Lateral aspect of an elbow joint: LUCL- Lateral Ulnar Collateral Ligament, AL - Anular Ligament, RCL - Radial Collateral Ligament, ALCL - Accessory Lateral Collateral Ligament.

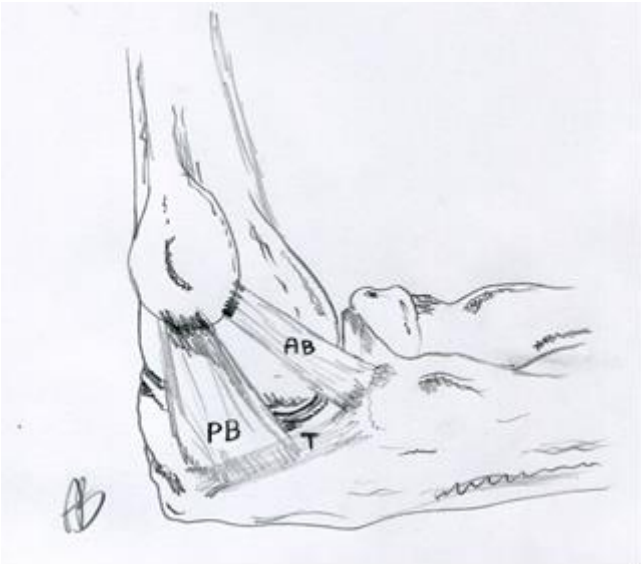

Figure 2. AB - Anterior bundle of the medial collateral ligament, PB - Posterior bundle of the medial collateral ligament T- Transverse Bundle.

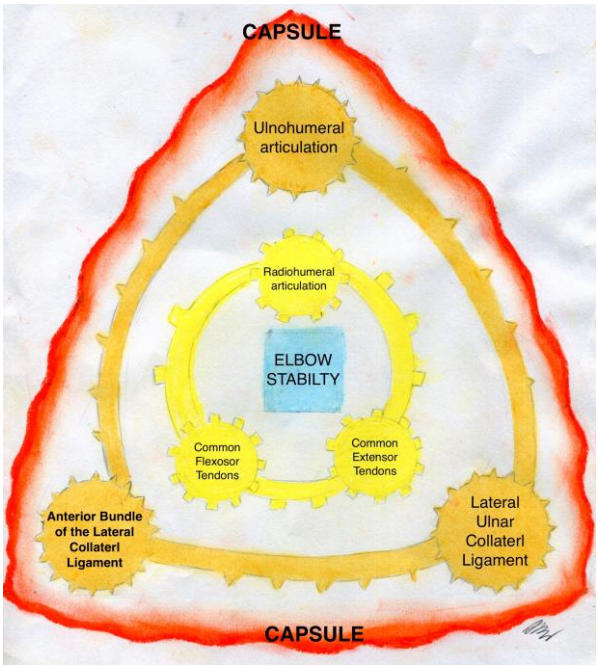

Figure 3. Primary and secondary elbow stability restraints. Adapted from O'Driscoll SW, Jupiter JB, King GJ, et al., The un-stable elbow. Instr Course Lect. 2001;50:91.

Pathophysiology

After (Robinson et al., 2017) one can distinguish the so called injury ladder for the most common posterolateral simple elbow dislocations. The injury starts typically medially and continues laterally. The cascade of events starts with rupture of medial collateral ligament, lateral ulnar collateral ligament disruption ,avulsion of common flexor origin, anterior capsule tear and eventually common extensor tendon avulsion from the lateral epicondale of the humerus (Figure 4). The aim of acute surgery is to reduce the risk of chronic instability by downgrading the injury: "bringing the patient down the ladder".

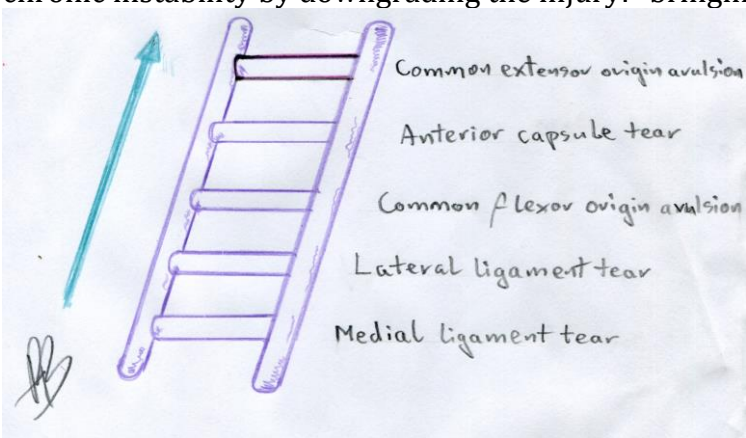

Figure 4. Injury ladder for the more common posterolateral simple elbow dislocations. The injury starts medially. Adapted from **Robinson, P. M., Griffiths, E., & Watts, A. C.** (2017) *'Simple elbow dislocation'* Shoulder and elbow, 9(3), pp 195–204.

AIM

The aim of this review is to present current state of art concerning diagnosis and treatment of simple elbow dislocations and to propose an algorithm, based on which one might successfully provide patient with adequate care.

MATERIAL AND METHODS

To start with, neurovascular limb status must be evaluated in search for ulnar nerve entrapment which typically elicits ulnar sided hand numbness or arterial disruption which might produce hand pallor and stiffness.

After ruling out nerve and vascular involvement, initial imaging should start with plain anteroposterior and lateral radiographs of the elbow (Rezaie et al. 2020). Radial head and ulnar coronoid process fracture most often in 33 % of complex cases. When there is doubt about joint congruency after joint reduction a CT scan is ordered and performed in search for bony avulsions or soft tissues impingement (Muhlenfeld et al., 2020) (Figures 5 and 6).

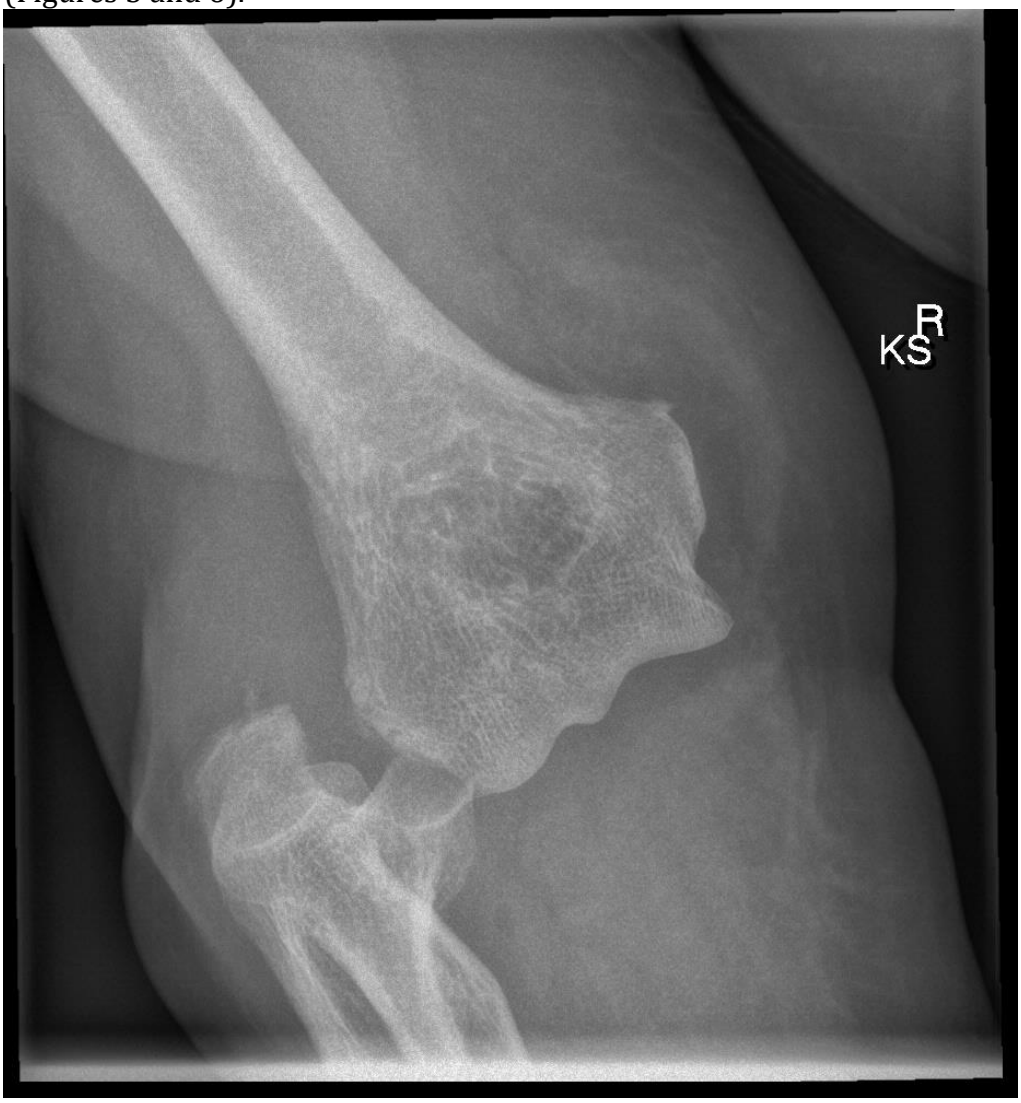

Figure 5. X-Ray AP view of posterolateral elbow dislocation.

Figure 6. X- Ray Lateral view of posterolateral elbow dislocation.

After having successfully reduced the elbow and controlled the neurovascular status of the extremity, the physician puts the injured hand in a sling and performs a control X-Ray scan to confirm reduction as well as to exclude accompanying fractures or joint incongruity as it might dramatically alter. consecutive treatment. Most of- ten the incongruity is caused by intra-articular X-ray permeable soft tissue or bony impingement that needs surgical release.
Following reduction, the elbow is assessed for stability through a full range of motion (ROM). On the occasion of gross instability presence, it will most commonly occur in full extension. If such a situation occurs, the forearm has to be fully pronated and stability is again assessed through a full ROM (McCabe, 2015).

RESULTS

Treatment

After settlement of primary diagnosis the joint reduction is performed. In acute setting an intra-articular 1% lidocaine injection gives desirable pain relief and helps during reduction maneuvers. In more demanding patients intravenous short acting analgesics such as fentanyl in combination with midazolam might be introduced provided that the patient is constantly monitored, not hypersensitive and well saturated.
There are several reduction methods described differing from one another by patient position and consecutive force direction.

1. Supine elbow maneuver. The patient has to lie supine with the injured elbow flexed and the forearm becomes supinated. One has to apply traction to the forearm while counter-traction is applied to the arm. Afterwards the medial or lateral displacement of the olecranon is reduced. Eventually, the olecranon is pushed distally to engage the olecranon fossa of the humerus (Rezaie et al. 2020).
2. Parvin prone maneuver. The patient lies prone with the injured arm hanging from the table. A traction is applied by the forearm downwards with one hand and the arm is pulled upwards with the other while pushing olecranon into its ulnar fossa.

3. Supine cross-table. The patient lies supine with the injured limb flexed over the table. An assistant places forearm into full supination and then applies traction while the physician pulls by the arm on the opposite side while trying to relocate olecranon gently pushing it back into the olecranon fossa thus completing reduction.

The elbow after reduction is placed in a hinged brace to allow therapy within the previously determined stable arc of motion. The brace allows mobilization while protecting the joint from either varus or valgus overload. The brace can be applied with the fore- arm fixed in pronation for patients with persistent instability in supination.(McCabe, 2015) (Figures 7 and 8).

Figure 7. X-ray AP view after reduction.

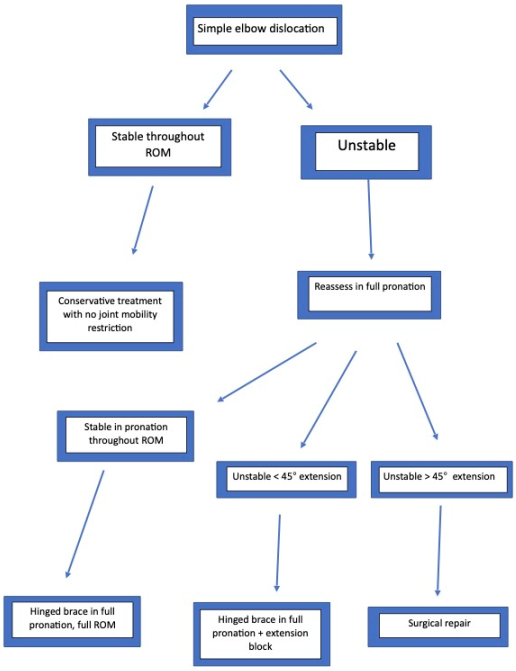

Figure 8. X-ray lateral view after reduction.

Treatment algorithm

In 2015 Armstrong proposed (Armstrong et al 2015) a treatment algorithm that is aimed at looking for those few dislocations that will need an operative approach. The proposal looks into three possible post-reduction scenarios:

1. The joint is irreducible or after reduction an incongruency remains
2. The joint is reducible and stable throughout ROM
3. The joint is reducible but unstable

If the joint is irreducible or after reduction, an incongruence remains an operative treatment should be advised. If the second case occurs a typical rehab protocol should be applied with no ROM restrictions (Figure 9).

In third case depending on the extent of instability different treatment is administered. If the joint is stable through arc of motion from 45◦ to 60◦ to full flexion active rehabilitation in stable arc should be applied with the arm placed in a hinged brace with or without extension block, additionally pronated or supinated relative to previous stability assessment, active rotation with elbow at 90◦. In a setting when the elbow remains unstable in above mentioned ROM an operative treatment should be indicated and a rehab protocol applied afterwards. Operative treatment in cases of simple elbow dislocations brings poorer effects than conservative treatment (Hackl et al., 2015).

Rehabilitation

Many authors in review of the literature advocate for as early mobilisation as possible and gradual increase of ROM (Armstrong, 2015; Singh et al., 2020) in simple dislocations (Robinson et al., 2017). Reported satisfactory results after applying rehabilitation protocol based on overhead exercises , which should start as soon as in 1 week post injury. The concept is established on the fact that there is a so called safe ROM zone that enables maintaining stability at same time allowing motion. The exercises should be performed while having the patient supine with the injured shoulder flexed to 90°, adducted and in neutral rotation. The setting allows to decrease the load directed posteriorly thus allowing the triceps to stabilize the joint. During exercises the patient avoids internal rotation and abduction, thanks to which the varus and extension-distraction stress is eliminated. This fact makes it possible for the lateral collateral ligament to heal without being extended. Every maneuver especially in first rehab faze should be performed under supervision of educated physiotherapist who meantime also helps to apply active-assisted motion to the joint.

Operative treatment

Although an operative treatment is not the subject of this study, it is agreed that in selected cases of complex and simple but unstable elbow dislocation early ligament repair and mobilization brings superior effects to conservative treatment in terms of remaining pain, instability or stiffness.

Long-Term Outcomes

It was reported by (Robinson et al. 2017) that the long-term functional effects of traditional treatment of simple dislocations with a hinged brace and early active full or restricted motion are generally acceptable and considered good. On an average of 24 months a recurrent dislocation or remaining instability are rare with valgus instability being the most common. Most commonly the post treatment complication is ROM limitation. It is generally unclear how long should the joint after reduction be immobilized in order to reduce complications rate but one can state generally that the shorter the better.

CONCLUSIONS

In conclusion, proper post-reduction stability assessment is a milestone in addressing the patient with the right treatment method. Provided that the patient is well classified and mobilized, the incidence rate of post traumatic stiffness or pain is uncommon and the results are favorable. In few cases of joints that remain unstable over 45° extension while testing in full pronation an operative treatment should be chosen and almost immediate post-operative active-assisted ROM induced.

REFERENCES

Armstrong, A. (2015) *'Simple Elbow Dislocation.'* Hand clinics, 31(4), pp. 521–531.

Calderazzi, F., Garzia, A., Leigheb, M., Menozzi, M., Nosenzo, A., Ceccarelli, F., Vaienti, E., & Pogliacomi, F. (2020) *'Simple and stable elbow dislo- cations: results after conservative treatment.'* Acta Bio Medica, 91 (4-S), pp. 224-231.

Hackl, M., Beyer, F., Wegmann, K., Leschinger, T., Burkhart, K. J., & Muller, L. P. (2015) *' The Treatment of Simple Elbow Dislocation in Adults: A Systematic Review and Meta-analysis.'* Deutsches Arzteblatt International, 112 (18), pp. 311-9.

McCabe, F. H. S., Michael P. (2015) *' Simple Elbow Dislocations: Evaluation, Management, and Outcomes.'* The Physician and Sportsmedicine, 40 (1), pp. 62–71.

Muhlenfeld, N., Frank, J., Lustenberger, T., Marzi, I., & Sander, A. L. (2020) *'Epidemiology and treatment of acute elbow dislocations: current concept based on primary surgical ligament repair of unstable simple elbow dislocations.'* European Journal of Trauma and Emergency Surgery, 46(5), pp. 1–8.

Rezaie, N., Gupta, S., Service, B. C., & Osbahr, D. C. (2020) *'Elbow Dislocation.'* Clinics in Sports Medicine, 39(3), pp. 637–655.

Robinson, P. M., Griffiths, E., & Watts, A. C. (2017) *'Simple elbow dislocation.'* Shoulder and Elbow, 9(3), pp. 195–204.

Singh, Elvey, M., Hamoodi, Z., & Watts, A. (2020) *'Current perspectives on elbow dislocation and instability.'* Annals of Joint, 6(10), pp. 1-15.